

Use of Reconstruction Nail in The Treatment of Ipsilateral Femoral Neck and Shaft Fractures

Syed Kamran Ali Shah, Asif Peracha, Sajid Younus, Asmatullah Khan, Kazim Rahim Najjad, Muhammad Arsalan Ghazi

ABSTRACT

Objective: To determine the effectiveness of ipsilateral femur- neck shaft fracture fixation with reconstruction nail at a tertiary health care centre.

Methods: This was a prospective observational study conducted from April 2014 to March 2016. Twenty-seven Patients were registered using a predesigned proforma. Inclusion criteria were either gender with age between 18 – 60 years with traumatic ipsilateral closed femur neck-shaft fracture. All patients registered subsequently underwent reconstruction nail insertion. The patients were followed in outpatient department after discharge at regular intervals to assess general recovery, complications and for assessment of fracture union.

Results: All 27 patients achieved union of neck fracture in average duration of 127 days. All patients except one femur shaft fracture union achieved in mean duration of 250 days. 25 patients (i.e., 93%) had good functional status at the time of radiological union of shaft fracture while 2 (i.e., 7%) had fair functional status. None of the patients developed avascular necrosis of neck of femur and all the patients returned to their preinjury activity level and occupation.

Conclusion: The current study suggests that reconstruction nail for the treatment of ipsilateral neck-shaft fracture of femur as a single implant produces acceptable clinical and functional outcomes if neck reduction is anatomically achieved. There is decreased blood loss with minimum soft tissue and periosteal disruption, which increases the possibility of fracture union. It is easier to address two fractures with single implant by reducing operating time and achieving possible high rate of radiological union with minimum risk of complications.

Key Words: Reconstruction Nail, Ipsilateral femoral neck-shaft fracture, Compression Screw

INTRODUCTION

Ipsilateral femoral neck-shaft fractures usually involve young population of our communities as a result of high-speed motor vehicle accidents and fall from height. The incidence of ipsilateral neck-shaft fracture ranges from 2.5% to 9% of all femoral shaft fractures [1,2] and with passage of time it seems to be increasing [3]. 50% incidence of missed neck of femur fracture has been shown in literature so early diagnosis and management is required to prevent non union and avascular necrosis of head of femur [4]

Ipsilateral femoral neck-shaft fractures are very rare and challenging combination of injury for orthopedic surgeon to manage [5,6,7]. Early

stabilization and fixation of fracture is main stay of treatment in these usual poly trauma patients [8]. Early diagnosis of femur neck fracture in association with shaft fracture facilitate timely fixation of fracture, which increases the chances of union and decreases the risk of femur head osteonecrosis [9].

Ipsilateral neck-shaft fracture is a rare entity creating a dilemma concerning the ideal fixation method. There are a number of recommended methods mentioned in literature for the treatment of this challenging entity of fracture [10] but none of method has been considered as treatment of choice [11]. It is very important to stabilize such complex fracture with stable internal fixation [12,13,14,]. Numerous implants have been recommended for the fixation of these injuries, but no consensus has been reached as to the optimal treatment strategy. For the management of ipsilateral neck-shaft fractures of the femur, it is very important to consider timing of fracture fixation, implant selection and sequence of fixation as well as selected implant should be able to

*Resident Orthopedics, Department of Orthopaedics
Liaquat National Hospital, Stadium Road, Karachi
Correspondence: Syed Kamran Ali Shah
Email: drkami1405@gmail.com*

maintain fracture reduction and stable fixation which is very crucial for early postoperative mobilization and reducing risk of complications along with increasing union rates [15, 16]. Reconstruction nails were introduced in 1986, and commercialized as Russell-Taylor reconstruction nails [17]. Reconstruction Nails were designed so that ipsilateral femoral neck-shaft fractures could be fixed by one single implant.

Internal fixation of the fractures with two separate implants provides better results in terms of fracture reduction and complication rates [18, 19]. But other studies suggest that use of single implant (Reconstruction nail) facilitate two-fracture fixation with ease of application and decreasing duration of surgery with reduced blood loss [20, 21].

The aim of our study was to evaluate the effectiveness of Reconstruction Nail for the management of ipsilateral neck-shaft fracture of femur as single implant for concomitant two fracture fixation due it's ease for application, minimum soft tissue disturbance, periosteal disruption and less blood loss during surgery with minimizing overall timing of surgery to achieve stable fixation with high rates of union if appropriate reduction achieved.

METHODS

This was a prospective observational study conducted from April 2014 to March 2016.

27 Patients were registered using a predesigned proforma. Inclusion criteria were either gender with age between 18 – 60 years with traumatic closed ipsilateral femur neck-shaft fracture.

All 27 patients were diagnosed with ipsilateral neck-shaft femur fractures. Relevant radiographs of the affected injured extremity were taken to classify the fracture. Anteroposterior and lateral views of the plain radiographs of pelvis and affected femur with knee were taken in emergency radiology room as a part of standard trauma assessment protocol. Out of 27 patients, 18 (67%) had fracture of femur at mid shaft, 4 (15%) proximal shaft and 5 (19%) distal shaft fractures. Patients were sub divided into Group A and B on the basis of displacement of neck of femur according to Garden classification. Group A (N=17) (Garden type I and II) and Group B (N=10) (Garden type III and IV). Femoral shaft fracture was classified according to Winquist and Hansen [22]. There were three type 0, four type I, sixteen type II and four type III fractures. Out of 27 patients, 7 (26%) patients had multiple

associated injuries including four had brain injuries, 3 (11%) patients with blunt chest and abdomen injuries.

Among 27 patients 24 (89%) had history of high speed motor vehicle accident, 2 (7%) patients with history of fall from height and one patient sustained ipsilateral femur neck and shaft fracture as a result of blunt trauma due to assault. All patients were treated with reconstruction nail and surgery were performed within average of 24 hours from the time of incident except patients with multiple injuries patients who were operated in average of 3 days after the fitness given from relevant involved specialty. Skeletal traction were applied to those patients who were not fit for surgery more than 48 hours due to other associated injuries and fitness issues.

Patients were shifted on traction table with extra care given to minimize risk of neck of femur fracture displacement during shifting. A reduction of neck of femur was achieved with closed maneuver (Whiteman manipulation maneuver) in 26 patients and in one patient reduction was achieved through open method via Smith and Peterson approach.

Reconstruction nailing incision was made from tip of greater trochanter to 5 cm proximally. Entry hole were made under image guidance with awl. After making entry hole, guide wire was passed. Reaming was done. Guide wire was exchanged from reaming guide to nail guide with the help of plastic hollow tube. Reconstruction nail was attached with assembly and checked with k-wire through cannula so it could engage screws. Reconstruction nail was introduced and needed to be hammered in or extracted few mm to permit two screws in the neck. Compression at fracture site was achieved with two screws. Distal locking screws were passed with fluoroscopic control and free hand technique. Patients were allowed strict non weight bearing with walker from 2nd post operative day and full weight bearing allowed till radiological and clinical sign of union confirmed. All patients were kept in follow up for average of one year period for the assessment of radiological signs of union and evaluation of patients' functional status assessed by using the assessment system of Friedman and Wyman at the time of radiological union of shaft fracture [23].

RESULTS

Out of 27 enrolled patients, 25(92.6%) were male and 2(7.4%) females, in which group A 16 (94.11%) was male and 1(5.88%) patient was female and in-group B 9(90%) were male and 1 (10%) was female. Mean age

in-group A was 33.47±3.72 years and in-group B was 32.82±3.71, overall mean age was 33.145±3.74. Overall mean operating time was 132.5 minutes but in-group A, 125 minutes and in-group B it was 140 minutes. Total mean blood loss was 200ml, in group A this mean loss was 180 ml and in group B was 220ml. Mean hospital stay was less than a week but length of stay was increased in those patients who had associated injuries which was average 7-12 days for seven

patients. The mean follow-up periods for all registered patients were 48.8 weeks. Radiographic union was assessed in follow-up, and it is defined as more than 80% of the fracture gap filled with bony trabeculae. The mean duration for radiological union of neck of femur fractures from surgical intervention to visible radiological union was 127 days, and for shaft of femur fractures was 250 days.

Table 1: Characteristics of patients with ipsilateral femoral neck-shaft fractures

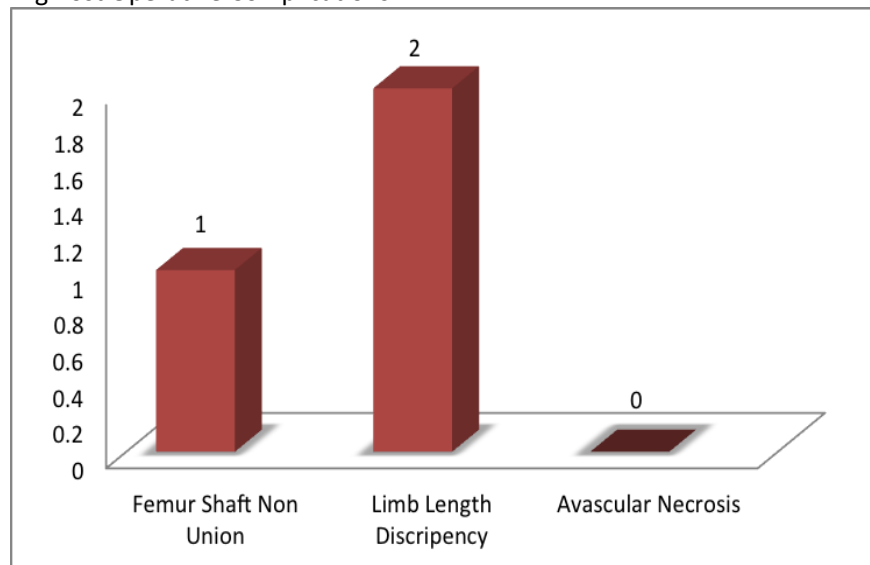
Group N=27	Mean Age Yrs	Sex Male/Female	Side Right/Left	Femur Neck Fracture (G.C) ¹	Femur Shaft Fracture (W.H) ²	Displaced/ Nondisplaced
A N=17	33.47	M=16 F=1	R=7 L=10	I=5 II=12	0=2 I=3 II=10 III=2	Nondisplaced
B N=10	32.82	M=9 F=1	R=7 L=3	III=9 IV=1	0=1 I=1 II=5 III=3	Displaced

1- Garden Classification, 2-Winquist and Hansen Classification.

Table 2: Treatment and perioperative assessment of ipsilateral femoral neck-shaft fracture patients

Group N=27	Mean Operating Time(min)	Mean Blood Loss(ml)	Mean Hospital Stay(days)	Follow-Up Period(weeks)	Rdiographic Union of Neck (Days)	Rdiographic Union Femur Shaft (Days)	Functional Outcome at 48 weeks
A N=17	125min	Mean 180ml	Mean 5.88±2.2	Mean 46.4	Avg = 117 days	Avg = 237 days	Good=16 Fair=1
B N=10	140min	Mean 220ml	Mean 6.4±2.3	Mean 51.2	Avg = 138 days	Avg = 255 days	Good=8 Fair=1

Bar Chart 1.0: Showing Post Operative Complications



Two patients in group B developed limb length discrepancy due to comminuted shaft fracture both are WH-III [21] and in both patients it was 2cm, one patient in group A developed femur shaft nonunion which was addressed by reoperation with bone grafting and finally fracture healing achieved. All registered patients were evaluated for functional status by using the assessment system of Friedman and Wyman at 48 weeks. All patients' functional status were good as per this criterion except two patients had fair functional outcome, one in group A and one in group B. None of the patients developed avascular necrosis of neck of femur and all the patients returned to their preinjury activity level and occupation.

DISCUSSION

Ipsilateral neck-shaft fracture of femur is a complicated injury usually resulting from high energy trauma. With passage of time, its incidence is increasing [3]. It is a challenging combination of injury for orthopedic surgeon to manage [5, 6, 7]. Early stabilization and fixation of this fracture combination in these usual polytrauma patients is important to decrease the morbidity and mortality associated with the option of long term traction [8]. Numerous implants have been recommended for the fixation of these injuries, but no consensus has been reached as to the optimal treatment strategy. The selected implant should be able to maintain fracture reduction and stable fixation for early postoperative mobilization with reduced risk of complications along with increased union rates [15,16]. Studies suggest that as compared to two separate implants for the ipsilateral neck-shaft fracture, use of single implant facilitates two-fracture fixation with ease of application and decreases duration of surgery with reduced blood loss [20, 21]. Reconstruction Nail is one of the implant through which this fracture combination can be fixed using a single implant.

We hypothesized that Reconstruction Nail is an effective implant for ipsilateral neck-shaft fracture in terms of less operating time, less blood loss, less hospital stay, high union rate and good functional outcome.

There are studies reporting the outcome of fixation of ipsilateral neck shaft fracture using Reconstruction Nail. SH Lin 2002 [24] observed the radiological union and functional outcome of 5 cases of ipsilateral neck shaft femur fractures treated with Reconstruction Nail.

All 5 cases of their study achieved radiological union in mean duration of 321 days. They observed that operating time, blood loss and duration of union of fracture was more in displaced fracture of neck (Garden III). The functional outcome of all their 5 patients as assessed by system of Friedman and Wyman was good.

Zubair Javaid 2012 [25] studied the radiological union in 16 cases of ipsilateral femur neck-shaft fractures treated with Reconstruction Nail. 13 of their cases achieved union in 3 to 6 months. 2 cases had delayed union of shaft fracture and 1 had non-union of shaft fracture.

We divided the patients in two groups according to the severity of neck of femur fracture. As expected, the operating time and the blood loss was greater in patients of group B with displaced neck of femur fracture (Garden III and IV). This coincides with the results reported by Friedman 1986 [23]. Concurring with SH Lin 2002 [24] and Zubair 2012 [25], all patients in our study achieved union of neck fracture. One patient had non-union of shaft fracture treated with bone grafting. The average duration of radiological union of neck fracture in our study was 4.25 months (about 128 days) and for shaft fracture it was 8.2 months (about 247 days).

Ipsilateral neck-shaft fracture is a combination, which usually results from high-energy trauma and associated mostly with the injuries to other systems. In these polytrauma patients, early mobilization and rehabilitation is imperative to prevent infections and cardiorespiratory complications such as deep venous thrombosis, pulmonary embolism, respiratory, urinary tract and other infections. To achieve this in a polytrauma patient with already less reserve, skeletal stabilization of these fractures with minimal operative duration, less blood loss and minimum soft tissue trauma is desirable. Our study is a continuation of the previous literature that Reconstruction Nail is an acceptable and favorable option for treating this fracture combination using a single implant with less blood loss and minimum periosteal disruption allowing quicker rehabilitation and favorable biological environment for fracture healing.

CONCLUSION

The current study suggests that reconstruction nail for the treatment of ipsilateral neck-shaft fracture of femur as a single implant produces acceptable clinical

and functional outcomes if neck reduction is anatomically achieved regardless type of neck of femur fracture according to Garden classification. There is decreased blood loss with minimum soft tissue and periosteal disruption, which increases the possibility of fracture union. It is easier to address two fractures with single implant by reducing operating time and achieving possible high rate of radiological union with minimum risk of complications.

REFERENCES

1. Neogi DS, Kumar KA, Trikha V, Yadav CS. Ipsilateral femoral neck and trochanter fracture. *Indian journal of orthopaedics*. 2011 Jan 1;45(1):82.
2. Watson JT, Moed BR. Ipsilateral femoral neck and shaft fractures: complications and their treatment. *Clin Orthop Relat* 2002 Res 399:78–86
3. Jain P, Maini L, Mishra P, Upadhyay A, Agarwal A. Cephalomedullary interlocked nail for ipsilateral hip and femoral shaft fractures. *Injury* 2004, 35(10):1031–1038
4. Clawson GK, Smith RF, Hansen ST. Closed intramedullary nailing of the femur. *J Bone and Joint Surgery* 1971; 53-A; 681-92.
5. Bennett FS, Zinar DM, Kilgus DJ. Ipsilateral hip and femoral shaft fractures. *ClinOrthop* 1993, 296:168–1776.
6. Gary JL, Taksali S, Reinert CM, Starr AJ. Ipsilateral femoral shaft and neck fractures: are cephalomedullary nails appropriate?. *Journal of surgical orthopaedic advances*. 2010 Dec;20(2):122-5.
7. Douša P, Bartoníček J, Luňáček L, Pavelka T, Kušíková E. Ipsilateral fractures of the femoral neck, shaft and distal end: long-term outcome of five cases. *International orthopaedics*. 2011 Jul 1;35(7):1083-8.
8. Goris, R. J. A. Gimbere, J. S. F. Vann Niekerk, J. L. M. Schoots, F. J. Booy, L. H. D. Early osteosynthesis and prophylactic mechanical ventilation in the multiple trauma victim. *J Trauma* 1982, 22:895–903
9. Boulton CL, Pollak AN. Special topic: Ipsilateral femoral neck and shaft fractures–Does evidence give us the answer?. *Injury*. 2015 Mar 31;46(3):478-83.
10. Casey MJ, Chapman MW. Ipsilateral concomitant fractures of the hip and femoral shaft. *J Bone Joint Surg Am* 1979, 61: 503–509.
11. Chaturvedi S, Sahu SC. Ipsilateral concomitant fractures of the femoral neck and shaft. *Injury* 1993, 24:243–246.
12. Alho A. Concurrent ipsilateral fractures of the hip and shaft of the femur. A systematic review of 722 cases. *Ann Chir Gynaecol* 1997, 86:326–336.
13. Friedman RJ, Wyman ET Jr. Ipsilateral hip and femoral shaft fractures. *ClinOrthop* 1986, 208:188–194.
14. Gill SS, Nagi ON, Dhillon MS (1990) Ipsilateral fractures of the femoral neck and shaft. *J Orthop Trauma* 4:293–298
15. Haidukewych GJ, Rothwell WS, Jacofsky DJ, Torchia ME, Berry DJ. Operative treatment of femoral neck fractures in patients between the ages of fifteen and fifty years. *J Bone Joint Surg Am* 2004, 86(8):1711–1716.
16. Swiontkowski MF, Hansen ST Jr, Kellam J. Ipsilateral fractures of the femoral neck and shaft. A treatment protocol. *J. Bone Joint Surg Am* 1984, 66(2):260–268
17. Russell TA. Ipsilateral femoral neck and shaft fractures. what have we learned? *Tech Orthop*1998;13:100–8.
18. Oh CW, Oh JK, Park BC, Jeon IH, Kyung HS, Kim SY. et al. Retrograde nailing with subsequent screw fixation for ipsilateral femoral shaft and neck fractures. *Arch Orthop Trauma Surg* 2006,126(7):448–453.
19. Peljovich AE, Patterson BM. Ipsilateral femoral neck and shaft fractures. *J Am AcadOrthopSurg* 1998, 6(2):106–113.
20. Hossam El. Shafie M, Adel Morseay H, Emad Eid Y. Ipsilateral fracture of the femoral neck and shaft, treatment by reconstruction interlocking nail. *Arch Orthop Trauma Surg*. 2001, 121(1–2):71–74.
21. Jain P, Maini L, Mishra P, Upadhyay A, Agarwal A. Cephalomedullary interlocked nail for ipsilateral hip and femoral shaft fractures. *Injury* 2004, 35(10):1031–1038.
22. Winquist RA, Hansen ST Jr (1980) Comminuted fractures of the femoral shaft treated by intramedullary nailing. *OrthopClinNorth Am* 11(3):633–648.
23. Friedman RJ, Wyman ET Jr. Ipsilateral hip and femoral shaft fractures. *Clin Orthop Rel Res* 1986;208:188–94.
24. Lin SH, Lo CW, Cheng SC, Kuo MY, Chin LS. Use of reconstruction nails to manage ipsilateral displaced femoral neck-shaft fractures: assessment of a new

approach. Journal of Orthopaedic Surgery. 2002
Dec 1;10(2):185.

25. Javaid Z, Rehman OU, Islam Uddin SF. Treatment
Evaluation of Concomitant Femoral Neck and Shaft

Fractures. Journal of Rawalpindi Medical College
(JRMC). 2012;16(1):28-30.