

Management of Infected Non Union Tibial Shaft by Ilizarov Method

ZULFIQAR A SOOMRO¹, ZAMIR A SOOMRO², SAEED A SAMO³

ABSTRACT

Objective: To assess the outcome of the management of infected non union of tibial shaft by Ilizarov method.

Patients and Methods: This prospective study was conducted at department of orthopedic CMC Larkana and GMMMC Sukkur from March 2008 to February 2011. Forty five patients with infected non-union of tibia with or without shortening and bone loss were included.

Results: 45 Patients were included in this study. Out of 45 patients, 27 were male and 18 were females. The average follow up period was 18 months. No patients have lost follow-up. No mortality was observed in current study. The overall success rate was 95%.

Conclusion: Management of infected non union of tibia is one of the most perplexing dilemma of orthopaedic surgery. Where as the traditional methods of treatment of infected non-union involve extensive operative exposure with repeated debridements, prolonged use of local and parenteral antibiotics, bone grafting and long period of immobilization. Ilizarov technique is minimally invasive, and apart from obtaining union with distraction/compression osteogenesis. This method has added advantage of immediate mobilization and early weight bearing.

Key Words: Infected non-union, Tibia, Ilizarov method

INTRODUCTION

The tibia is one of the most common bones vulnerable to open injuries leading to soft tissue loss. Osteomyelitis of the tibia and infected non-union are the most severe complications after open tibial fractures and not infrequently necessitate amputations. Of all the prognostic fracture characteristics, described by Nichol, that implying the worse prognosis was infection.¹

Infection is most frequent after high velocity open injuries with skin necrosis or skin loss and after ORIF with failed flaps or skin coverage and metallic infections. For getting rid of infection, achieving bony union and functional limb often requires courageous measures, with increasing risk of failure or amputation.² There are many methods available for management of chronic diaphyseal infections, including extensive debridement, drainage of the infected area with antibiotics, local soft tissue rotational flaps, packing the defect with antibiotics impregnated beads, papineau type open cancellous bone grafting, tibio-fibular synostosis, cancellous allograft in fibrin sealant mixed with antibiotics and free micro

vascular soft tissue and bone transplant. Ilizarov technique of distraction histogenesis is a valuable addition to the surgical options for non-union treatment has occurred, although frequently applied to the most difficult non unions with bone loss, infection and shortening, this treatment has often made the difference between amputation and functional restoration of the extremity.³ The ability to stimulate neo-osteogenesis by means of the tension effect permit us to encourage healing of bone fragments, restore length and thickness of osseous tissue and also activate biosynthetic process there by increasing local resistance to infection.⁴

- A. Controlled osteogenesis, resulting in filling of cavities of newly formed tissue.
- B. Resection of the infected bone and subsequent inter-calary bone lengthening.
- C. A technique involving gradual transport of one wall of the cavity (with its attached soft tissue) there by obliterating the cavity with new bone tissue⁵.

A common saying by Ilizarov "Infection burns in the fire of regenerate". Under appropriate circumstances, we can apply axial compression to a septic pseudoarthrosis and expect both osseous union and elimination of the infection, for this

Correspondence: Dr. Zulfiqar A Soomro, Department of Orthopedics, ¹GMMMC Sukkur

strategy to work effectively both bone ends must be viable.⁶⁻⁹

1. To define the indications of its use as opposed to more conventional methods.
2. To develop a protocol of application of this method in our own situations and in various cases of infected non-union with or without bone loss.
3. To ascertain the incidence of complications and advise methods prevent them.
4. To determine various risk factors which contribute to these complications.
5. To assess the final results.

MATERIAL AND METHODS

This study includes 45 patients from different districts of Sindh province and also from lower Punjab and Baluchistan, who reported to O.P.D Of Orthopaedic GMMMC Sukkur and CMC Larkana from March 2008 to February 2011, with infected non-union of tibia with or without shortening and bone loss. Out of these 27 were males while females were 18. The age of these patients ranged from 12-60 years with average of 35 years. All the forty five patients with infected non-union tibia, who attended Orthopaedic O.P.D, the main criteria for selection of the patients was difficulty or inability to bring the remarkable functional results by other existing conventional methods, so all patients were applied Ilizarov ring fixator, for control of infection by suitable antibiotics according to culture and sensitivity, thorough debridement, skin and muscle flaps for covering soft tissue defect and distraction histogenesis for filling skeletal defects.^{10,11} Following variety of patients were included in this study.

- (i) Infected non-union with un-operable skin and uncontrolled infection.
- (ii) Persisting infection with loosening of metal.
- (iii) Non-union with segmental bone loss.

Every patient was informed about the prolonged treatment, during which the fixator would be in place and was prepared psychologically to accept it. The patient support services at home were also evaluated as to whether he will be able to care for the fixator and pin sites after discharge from the hospital. Patients were also informed about the possible complications and expected results and also meeting between patient who has been operated and applied Ilizarov ring fixator with new patients for inter changing of views and sharing experience.^{12,13}

Once the patient was willing to undergo this method of treatment, a detailed preoperative work up was carried out, including a detailed history, in which the time, mode and duration of illness was noted.

Any previous operation and treatment were recorded. A thorough physical examination was carried out, in which apart from general examination, detail local examination was done which include the measurement of segmental tibial defect in cases of bone loss both on x-ray and on clinical examination, at the same time any associated deformity was also noted. Wound condition or discharging sinuses, type of discharge was also examined and pus sent for culture and sensitivity. Orthoroentgenograms were taken to exclude any deformity of limb segment with the help of specially illuminated table top. Through the line diagrams, the position of rings and site of corticotomy for bone transport, for correction of deformity, placement of special hinges and distraction rods where indicated was planned. All the routine investigations like complete blood picture, urine detail report, x-ray chest with E.C.G where required was also done and anesthetic opinion taken if the patient had some associated medical illness such as diabetes mellitus, hypertension or ischemic heart disease. Patients was then given final date for admission and operation.

Eleven patients (24.2%) also had associated deformities as stiff 8 (17.7%) cases and equinus foot in 3(6.6%) patients cross leg flap was done to cover large soft tissue defect prior to the application of Ilizarov ring fixator and in 1(2.2%) case rotational muscle flap (gastrocnemus muscle flap) was done in the ring fixator sonogram was done in 7 (15.5%) patients and whole the necrotic bone segment was removed. Corticotomy was performed in proximal metaphyseal region in 18 (40%) cases for bone transport and also for improving perfusion in order to fill skeletal gap in non-union with bone loss and in atrophic non union for controlling infection. The average initial operating time was 2.8 hours (range 1.8-4.2 hours). After corticotomy, latency period of 5 day (4-6) days was observed before distraction to allow early good quality callus formation. There after distraction commenced at a rate of 0.25 mm every 6 hourly/ day.¹⁴

According to Paley's et al classification, all these 45 patients were grouped in to A and B,

which were further divided according to mobility, bone loss with or without shortening.¹⁵

Post operative mobilization was largely dictated by the nature of injury with bone loss. Nevertheless, all patient were mobilized very next day of application of Ilizarov apparatus with partial to full weight bearing as tolerated by the patients.^{16,17}

Physical therapy was begun on second day of operation and pin tract dressing were changed on alternate day. Pin tract care was consisted of cleaning the sites with methylated spirit by residents and by nursing staff until the patient demonstrated competence in their own care. Distraction nuts for transporting bone segment were also moved by co-worker residents until patient's demonstrated competence in their own.

RESULTS

During the period from March 2008 to February 2011 (3 years study), a total of 45 patients with infected non-union of tibial shaft were treated in our units and all of them were included in this study. There were 27 males (60%) and 18 female (40%) and age of these patient ranged from 12-60 years, maximum incidence was seen in age range 25-38 years, in majority of cases lower 3rd tibia was involved in 18 (40%) mid 3rd in 16 (35.5%) cases and 11 (24.4%) proximal 3rd tibia right side was predominantly involved in 28 (62%) of all these patients were divided in to groups according to Paley's et al¹⁸ classification. Group "A" consisted of patient with type "A" non-union, with bone loss less than 1 cm, having fixed hypertrophic and lax non-union associated with or without deformity, in this group 31 (68.8%) patients were included. In group "B" patients with type "B" non-union having bone loss more than 1 cm which were further divided into (B1) non-union with bone loss without shortening in this group 5 (11.1%) patient were included. Group "C" (type B2) patients with shortening without bone loss, in this group 6 (13.3%) patients were included and group "D" (type B3) patients with bone loss and shortening, in this group 3 (6.6%) patients were included. A part from the primary procedure some sort of secondary procedure were also required during their follow up. Some of these procedures were carried out in out-patients, like minor adjustments where as most of them required hospitalization and some sort of anesthesia. The most common secondary procedures were readjustment of ring fixator 13 times in 10 (22.2%) cases, repetition of

corticotomy in 2 (4.4%) cases and bone grafting was done in 4 (8.8%) cases.

Any untoward occurrence during or after the treatment was considered as complication. These were divided into minor complications, which responded to non-operative treatment and did not result in lasting sequelae, and major complications, which required an operative procedure to correct it and which resulted in prolongation of treatment or compromised the outcome or a lasting sequelae. The average duration of follow up was 30 months (ranging from 6 to 36 months).

The results were divided in to bone-results and functional results according to the criteria laid down by ASAMI (Association for the Study of the Methods of Ilizarov).¹⁹

According to this system bone results were excellent in 33 patients (73.3%) good in 5 patients (11.1%) and poor in 3 patients (6.7%).

The functional results were based on five criteria; noteworthy limp, stiffness of either knee or the ankle (a loss of more than 15 degrees of full extension of the knee or 15 degrees of extension (dorsiflexion) of the ankle in comparison with the normal, contralateral ankle), soft tissue sympathetic dystrophy, pain that reduced activity or disturbed sleep and inactivity (unemployment) or an inability to daily activities because of the injury).

The functional result was considered excellent if the patient was active (that is not inactive according to the definition just given) and some of the other four criteria were applicable, good if the patient was active but three or four of the other criteria were applicable, and poor regardless of whether other criteria were applicable.

About 37 (82.2%) patients were able to return to work or activity they were doing prior to treatment. 11 (24.4%) patients had stiffness of either knee or ankle. Four patients had soft tissue atrophy. Five patients had persistent pain which interfered in activity and sleep.

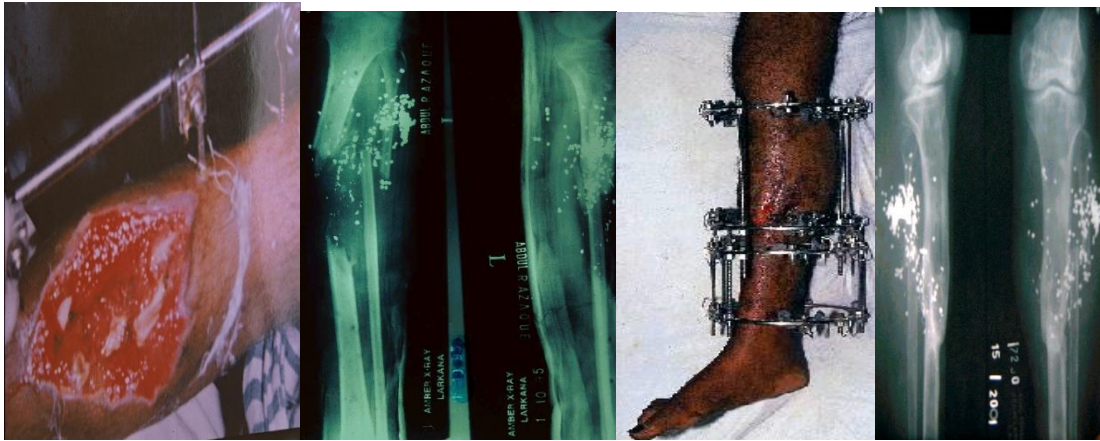
According to this criteria, the functional results were excellent in 13 (28.8%) cases, good in 18 (40%) fair in 8 (17.9%) and poor in 6 (13.3%).

DISCUSSION

The Ilizarov technique, pioneered in Soviet Union in the 1950, with new concept of distraction histogenesis is a valuable addition to the surgical options for non-union treatment has accrued.²⁰ Although frequently applied to the most difficult non-union with bone loss, infection and shortening,

associated with or without any other deformity, this treatment has often made the difference between

amputation and functional restoration of the extremity.²¹ In this study road traffic accidents with



open fracture of tibia associated with soft tissue loss came out to be the single most common cause of infected non-union tibia, out of 45 patients 23 (51.1%) were cases of road traffic accidents, 12(26.6%) were the cases of gun shorts and 10 (22.2%) were cases of post operative infections.²²

A part from primary problem, 18 (40%) patient had associated deformities, as still knee and ankle in 06 (13.3%) patients, equinus foot in 3 (6.6%) patients and 6 (13.3%) had angulation more than 17° and in 3 (6.6%) patient rotational deformity with translation.²³ The duration of hospital stay after fixator application was generally found to be proportional to the complexity of the procedure done. Maximum duration of hospital stay was 70 days and minimum was 10 days. The results were divided into Bone results and Functional results, according to criteria of ASAMI (Association for the Study and Application of Methods of Ilizarov).²⁴

Among the bone results, we had excellent and good results in 38 patients (84%), four (8.8%) patients had fair results and 3 (6.6) had poor results, out of which one has re fracture of regenerate²⁵, which was later applied bone graft and cast, but again graft site became infected and patient landed into infected draining non-union.²⁶ As for as the functional results were concerned, we were able to achieve excellent and good results in 31 (68.8%) of our patients, fair results in 8 (17.7%) cases and 6 (13.3%) in poor results.

In above mentioned patients with fair and poor results, the reasons were multifactorial. Most of them were with open fractures and internal fixation which later landed into infection, had history of other chronic major illness²⁷, had history of multiple surgeries ranging from five to fourteen

times, these multiple procedures were POP casts, widow dressings, internal fixations, repeated debridements and others. Considering the amount of surgeries and number of complications the patients suffering the end result of fair and poor grade seems quite reasonable.²⁸

CONCLUSION

Management of infected non union of tibia is one of the most perplexing dilemma of orthopedic surgery. Traditional methods of treatment of infected non-union involve extensive operative exposure with repeated debridement's, prolong use of local and parenteral antibiotics, bone grafting and long period of immobilization. Whereas the Ilizarov technique is minimally invasive, and apart from obtaining union with distraction/ compression osteogenesis.

REFERENCES

1. Rockwood CA, Green DP, Bucholz RW. Rockwood and Green's fractures in adults. London: Saunders, 1996, 2180–92.
2. Canale ST, Beaty JH. Campbell's operative orthopaedics. 12th ed. Philadelphia: McGraw-Hill, 2013; 2590–9.
3. Rockwood CA, Bucholz RW. Rockwood and Green's fractures in adults. London: Saunders, 1996; 2: 2181-21.
4. Richard H. Lange, Limb reconstruction versus amputation decision making in massive lower extremity trauma. Clinical Orthopaedics and related research No.243 page: 92, June 1989.
5. Ilizarov GA. Transosseous osteosynthesis. Heidelberg: Springer Verlag 1991; 495-96.

6. Worthier W. Operative principles of Ilizarov” Baltimore: Saunders 1991; 240-60.
7. Buckalter JA. Specialty of orthopaedics. London: Saunders, 5th ed 1994; 3-11.
8. Klein DM, Caliguri DA, Riina J, Katzman BM. Spontaneous healing of a massive tibial cortical defect. J Orthop Trauma 2012; 11: 2-3.
9. Dendrinis GK, Kontos S, Lyritis E. Use of Ilizarov technique for treatment of non-union of the tibia associated with infection. JBJS 1995; 77(6): 835-46.
10. Skoff HD. Bone marrow/allograft component therapy: a clinical trial. Am J Orthop 1995; 24(1): 40-7.
11. Gitelis S, Heligman D, Quill G. The use of large allografts for tumour reconstruction and salvage of the failed total hip orthoplasty, Clin Orthop 1988; 33: 62-70.
12. Bhan S, Mehara AK. Percutaneous bone grafting for non union and delayed union of fractures of the tibial shaft. Intern Orthop 1993; 17(5): 310-12.
13. Cattaneo R, Catagni M, Johnson EE. The treatment of infected non-unions and segmental defects of tibia by the methods of Ilizarov. Clin Orthop Relat Res 1992; 13: 143-52.
14. Bassett and associates Rockwood & Green’s fractures of adults. 1996;2:2179-80.
15. Aronson J. Factors influencing the choice of external for distraction ostogenesis. In: Barr JS Jr, ed. AAOSS instructional course lectures, Park Ridge: American Academy of Orthopaedic Surgeons, 1990, 38: 175-83.
16. Aronson J. Proper wire tensioning for Ilizarov external fixation techniques. Orthopaedics 2012; 27: 2990.
17. Bagnoli G, Paley D. The Ilizarov method. New York, A.B.C Decker, 1990.
18. Paley D, Fleming B, Catagni M, Kristiansen T, Pople M. Mechanical evaluation of external fixator used in limb lengthening. Clin Orthop 1990; 250: 50-55.
19. Leonard JW. Tension structures: behavior and analysis, New York: McGraw-Hill, 1988.
20. Aronson J, Harrison B, Cannon DJ, Lubansky HJ. Mechanical induction of osteogenesis: the importance of pin rigidity. J Pediatr Orthop 2010; 8: 396.
21. Sehwartsman V, Sehwartsman R. Corticotomy. Clin Orthop Relat Res 1992; 11: 37-7.
22. Paley D, Tetsworth K. Percutaneous osteotomies, & Giglisaw technique. Orthop Clin North Am 1991; 613-24.
23. Aronson J, Shen XG. Experimental healing of distraction ostogenesis comparing metaphysical and diphyseal sites, Clin Orthop Relat Res 1994, 25-30.
24. Golyakhovsky V, Frankel VH. Operative manual of Ilizarov technique. Philadelphia: St. Louis Mosby, 1993: 3-50.
25. Banznoli G. The Ilizarov method. Philadelphia: BC Decker 1991; 19-48.
26. Kummer FJ. Biomechanics of the Ilizarov external fixator. Clin Orthop Relat Res 1992; 280: 11-4.
27. Barbarossa V, Matkovic BR, Vucic N, Bielen MB, Gluhinic M. Treatment of osteomyelitis and Infected Non-union of the femur by a Modified Ilizarov technique: follow-up study. Croat Med J 2001; 42(6): 634-41.
28. Paley D, Cattaneo R. Ilizarov treatment of tibial non –union with bone loss. Clin Orthop Relat Res 1989;241:146.