

## Outcome of Elastic Intramedullary Nailing of Femur Shaft Fractures in Children

Salik Kashif, Bahadar Ali Khan, Ihsanullah, Khurram Iqbal, Muhammad Siraj, Noor Rahman, Mahmood ul Hasan

### ABSTRACT

**Objective:** To determine the outcome of elastic intramedullary nailing of femur shaft fractures in children in terms of fracture union, final wound healing, range of movement, limb lengths and gait of the patient.

**Methods:** We conducted a prospective study of 17 children presenting with femoral shaft fractures in Mercy Teaching Hospital from March 2014 to June 2015. The average follow up duration was 14 months (ranging from 9 to 22 months).

**Results:** 15 (88%) out of the 17 patients had excellent outcomes in terms of fracture union, final wound healing, range of movement, limb lengths and gait. One patient went into non-union who required an additional surgery, bone grafting to achieve union. The other patient had knee stiffness not responding to physiotherapy, thus needed manipulation under anesthesia.

**Conclusion:** It is concluded that Elastic Intramedullary Nailing of Femur Shaft Fractures in Children have excellent outcome with minimal complications. Therefore, orthopedic surgeons should adopt this procedure for the fixation of femoral diaphyseal shaft fractures.

**Keywords:** Femur shaft fractures, children, Elastic Intramedullary Nails, Outcome.

### INTRODUCTION

Femoral shaft fractures are the second most common fractures that occur in children [1,2], they comprise of 1-2% of all fractures occurring in children [3]. Most of them present as an acute injury and life-threatening injuries need to be excluded initially. Traditionally they have been managed conservatively with hip spica or traction, but recently the trend is towards fixation and early mobilization. Surgical options include fixation with dynamic compression plates, rigid intramedullary nails, external fixators and elastic intramedullary nails [4]. The goals of fixation are anatomical reduction, stable fixation, avoiding physeal injury, early mobilization with minimal complications.

The procedure of elastic intramedullary nail fixation of long bones (femur, tibia, humerus, radius and ulna) fractures in children is very popular [5, 6], but not the only method of fixation in developed countries. The advantages of elastic intramedullary nails over the other methods are many which include; it is a closed

reduction and internal fixation in which the fracture site is not opened, the fracture hematoma is not disturbed, hence more physiological and rapid healing; there are very small stab incisions which require one or two stitches at the most, so greater cosmetic effect and early wound healing; anatomical/near anatomical reduction; the proximal and distal physis are completely spared, so minimal chance of deformity in future; early mobilization of the knee, minimal chance of stiffness and early weight bearing. The stay in hospital is reduced [7], and the fracture generally heals within eight to ten weeks [8]. Disadvantages are few which include; it is a technically demanding procedure and has a large learning curve, rarely loss of fixation due to poor technique i.e. no 3 point fixation and there is a small chance of wound infection, nail removal requires another procedure although minor but requires general anesthesia.

Elastic intramedullary nail is the preferred treatment in children with femoral shaft fractures 4 to 12 years of age. It is argued that children under the age of four years tolerate hip spica very well and fracture unites readily with greater potential of remodeling<sup>9</sup>. Over 12 years, it is generally considered that there is increased risk of angulation of the fracture with elastic intramedullary nails [9], and there is less potential for remodeling, so a more rigid type of intramedullary nail

---

*Department of Orthopedic Unit, Mercy Teaching Hospital, Peshawar*

*Correspondence: Salik Kashif  
Email: salikkashif@gmail.com*

is preferred. There is a documented evidence of increased risk of avascular necrosis of the femoral head with the use of rigid intramedullary nails [10]. With external fixators, there is increased risk of knee stiffness and evidence of delayed and non-union [11].

Due to these reasons it was preferred to treat femur shaft fractures in children with elastic intramedullary nails. The aim of this study was to present our experiences regarding the outcome of femur shaft fractures treated with elastic intramedullary nail fixation in our institution.

## **METHODS**

The study was conducted in the Orthopedic and Trauma Unit of Mercy Teaching Hospital, Peshawar, after taking Ethical approval from IREB. Between March 2014 and June 2015, 17 consecutive children with displaced femoral shaft fractures underwent closed reduction and internal fixation with elastic intramedullary nails in our unit, after taking informed and written consent. The age range was 4 years to 11 years (mean 7.9 years). All children underwent the procedure under general anesthesia. Surgery was done on traction table. Initially the fracture was reduced by traction and/or manipulation and was checked under image intensifier. Next the patient was draped after scrub. Two or three elastic nails were used, such that they occupied more than 80% of the medullary canal diameter. The nails were precontoured with the apex of the curve towards the fracture site. The point of entry for all nails was retrograde i.e. distal to proximal. Incisions were made, we prefer to make the lateral incision initially. The entry point of the nail was confirmed again under image and the entry hole was made in the bone. The nail was then inserted up to the point that it would just cross the fracture site. The medial pin was then inserted with the same method. Compression was achieved once the nails crossed the fracture site. The nails were advanced until they were embedded in the proximal metaphysis. The final position was checked under image intensifier. All the elastic nails were cut deep so that they would not impinge the skin and the wounds were closed. No additional supports, i.e. posterior slabs or casts were applied after fixation. A single orthopedic surgeon with pediatric orthopedic experience did all the procedures.

Post-operatively the knee was mobilized on the 1st postoperative day in all patients. Weight bearing was decided by the fracture type and adequacy of

reduction. The mean duration of immobilization was 41 days (1- 62 days).

The data was collected prospectively in a Performa which included patient biodata, mechanism of injury, the type of fracture, duration of injury, the diameter of the nails used, complications and outcome of the procedure in terms of wound healing, fracture union, range of movement, limb lengths and the gait just prior to and after removal of the nails.

## **RESULTS**

A total of 17 femoral shaft fractures were treated with elastic intramedullary nails. In 3 cases, after repeated attempts of unable to align the fracture ends by closed reduction during surgery, a small incision was made at the fracture site to aid in the reduction process, they were excluded from the study. The total number of cases after exclusion of these 3 fractures (requiring open reduction) was 17.

Of these, 8 fractures were the result of road traffic accidents (RTA), 6 resulted from fall from height and 3 from sports injuries. 15 fractures were closed fractures while one sports injury patient had a Gustilo & Anderson type 1, and one RTA patient with fracture had a type 2 wound. 8 involved middle 3rd of the shaft, 5 proximal 3rd and 4 distal 3rd of the shaft fractures. 7 femoral shaft fractures had a transverse pattern, 4 were oblique, 4 had spiral configuration, 2 were multifragmentary fractures.

The patients with femur fractures were admitted in orthopedic department both as emergency and elective cases. The fractures were fixed on the next available regular list. The time taken for the fractures to be fixed ranged from 1 to 6 (avg 2.8) days after the initial trauma, shown in Table.

15 out of the 17 fractures were fixed with 2 nails, while in 3 nails were used in two patients.

The average follow up duration was 14 months (9 to 22 months). Radiological consolidation was seen within 2 months in 14 out of the 17 patients, at this point all of them were mobilized full weight bearing.

15 out of the 17 fracture (88.2%) healed satisfactory or with minor complications (knee stiffness, superficial wound infections, delayed union). 4 had knee stiffness, 3 of them responded to physiotherapy and one required manipulation under anesthesia. Stiffness in the three knees resolved with physiotherapy of one month at the most. There were 2 cases of superficial wound infection, both responded to oral antibiotic according to culture and sensitivity.

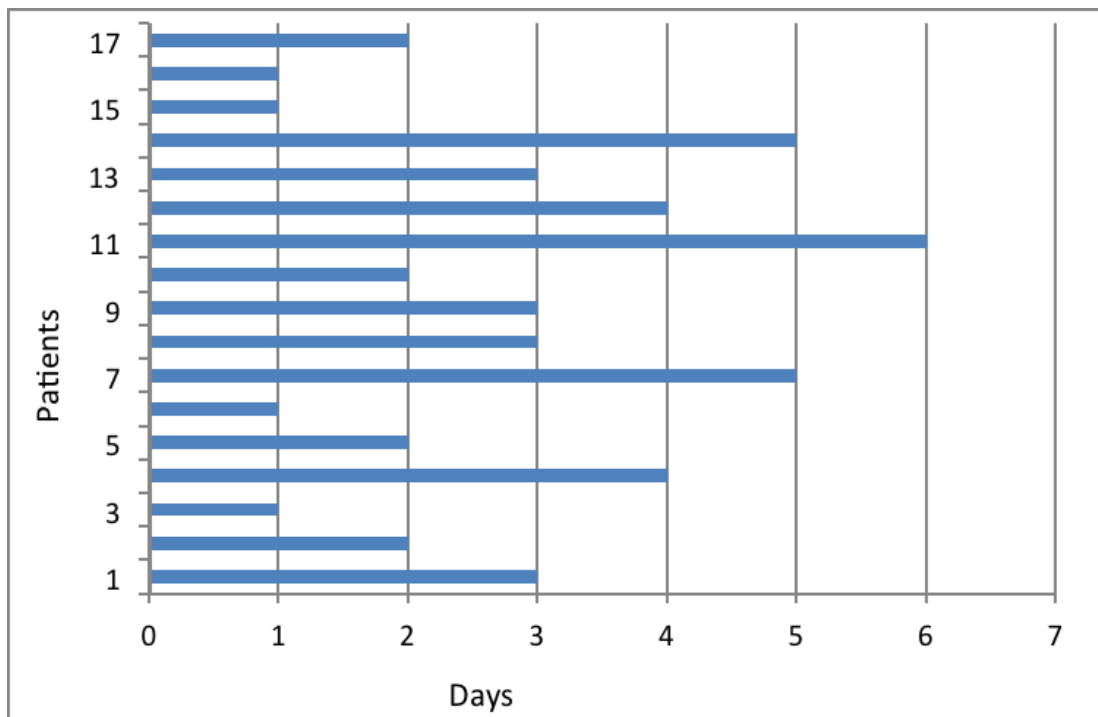
2 patients showed delayed consolidation and one oblique fracture went into non-union, which required another surgery (bone grafting) to achieve union. This was a 10 years old boy, victim of road traffic accident, had a closed oblique fracture at the mid-shaft femur. Emergency stabilization was done immediately and the fracture was fixed with two nails on the next available list (3 days from injury). The reason for the non-union was presumed to be a gap at the fracture site and the patient was reluctant for weight bearing and physiotherapy.

The nails were removed when the fracture had completely united. Majority of the nails were removed between 7 and 10 months. In 2 patients there was delayed union and the nails were removed at 12 and 13 months. One non-union required bone graft; the nail of these patients was removed at 16 months.

At the final follow up, the range of movements at the knee and hip joints were normal (full range), and there was no abnormality in the gait of all the patients.

There was no difference in the outcome between left and right femurs, nor was there any difference between male and female patients.

**Table:** Showing the time taken (in days) to fixation after the trauma



## DISCUSSION

The advantages of immediate surgery for displaced femoral shaft fracture in the pediatric population are many and include anatomical/near anatomical reduction, immediate mobilization, early weight bearing, less chances of joint stiffness and malunion. The disadvantages includes a surgical scar, potential infection, implant failure. These disadvantages are minimized when the fracture is closely reduced by manipulation and fixed with elastic intramedullary nails.

The procedure is done under general anesthesia and a traction table is used for reduction, but some

surgeons do not use traction table for reduction. Instead, they manipulate the fracture site freely and insert the nails. There are studies in which the nails can be inserted from the proximal metaphysis distally, with equally good results.

We used the C configuration of the elastic nails, some surgeons advocate to contour the nails in the S fashion and argue that they have a better fixation i.e. 4 point fixation as compared to the C configuration which have 3 point fixation<sup>11</sup>. We have no experience with the S configuration.

Our results are comparable with the series of Hassan 2015 [12], who reported a 85.2% excellent

result in 27 patients treated with elastic intramedullary nails for femoral shaft fractures.

The number of minor complications in our study was 8 (2 delayed unions, 4 temporary knee stiffness, and 2 cases of superficial wound infection which responded to oral antibiotics). This number seems high but in many international studies the percentage of minor complications approaches to around 50% [13].

In our series, we removed the nails between 7 and 10 months, which is a little delayed as compared to other studies<sup>14</sup>. The reason is not fully understood, but most of our patients came for follow-up quite late contrary to the advice.

One minor concern is growth disturbance of the ipsilateral femur, not due to injury of the physis but due to increased blood flow to the ipsilateral femur and hence the physis is overactive and the femur overgrows, but it is very minimal with 1.2mm of overgrowth reported by Ligier 1998 [14]. We have not observed any overgrowth in our patients. In fact, in the two patients with multifragmentary fracture, there was minimal 0.5-1cm shortening due to compression of the fracture fragments after weight bearing, although this was anticipated and weight bearing was delayed, but still it occurred.

One author has questioned the necessity of the removal of the nail [15], but we believe that the nail can cause symptoms and problems later and favor its removal routinely after complete union.

The nails may be of Titanium or Stainless Steel [16]. If titanium nails are to be used the diameter should be larger as compared to stainless steel, because they are more flexible, hence can cause malunion [17]. We prefer the use of Titanium nails because we believe greater flexibility causes a better 3-point fixation.

There are limitations in this study, which include; a small sample size and the patients were not followed up to skeletal maturity. The malunion could very well remodel, if followed till maturity. We hope that future studies will overcome these limitations.

## CONCLUSION

In conclusion, it is strongly recommended that orthopedic surgeons start using elastic intramedullary nails for the fixation of femoral diaphysial shaft fractures, although technically demanding, but a qualified orthopedic surgeon requires little training to learn this technique and further cases to master it. Moreover, no special or expensive equipment is required in order to perform this procedure, although

the price of these elastic nails is more as compared to the other methods of fixation.

## REFERENCES

1. Hedström EM, Svensson O, Bergström U, Michno P. Epidemiology of fractures in children and adolescents. *Acta Orthop*. 2010;81:148–53.
2. Heideken J, Svensson T, Blomqvist P, Haglund-Akerlind Y, Janarv PM. Incidence and trends in femur shaft fractures in Swedish children between 1987 and 2005. *J Pediatr Orthop*. 2011;31:512–9.
3. Mäyränpää MK, Mäkitie O, Kallio PE. Decreasing incidence and changing pattern of childhood fractures: a population-based study. *J Bone Miner Res*. 2010;25:2752–9.
4. Ramseier LE, Janicki JA, Weir S, Narayanan UG. Femoral Fractures in Adolescents: A Comparison of Four Methods of Fixation. *J Bone Joint Surg Am* 2010;92:1122-9.
5. Barry M, Paterson JM. Flexible intramedullary nails for fractures in children. *J Bone Joint Surg [Br]* 2004;86-B:947-53.
6. Furlan D, Pogorelič Z, Biočić M, Jurić I, Budimir D, Todorić J, et al. Elastic Stable Intramedullary Nailing For Pediatric Long Bone Fractures: Experience With 175 Fractures. *Scandinavian Journal of Surgery*. 2011;100:208–15.
7. Greisberg J, Bliss MJ, Ebersson CP, Solga P, d'Amato C. Social and economic benefits of flexible intramedullary nails in the treatment of pediatric femoral shaft fractures. *Orthop* 2002;25:1067-70.
8. Flynn JM1, Hresko T, Reynolds RA, Blasler RD, Davidson R, Kasser J.. Titanium elastic nails for pediatric femur fractures: a multicenter study of early results with analysis of complications. *J Pediatr Orthop* 2001;21:4-8.
9. Luhmann SJ, Schootman M, Schoenecker PL, Dobbs MB, Gordon JE. Complications of titanium elastic nails for pediatric femoral shaft fractures. *J Pediatr Orthop* 2003;23:443-7.
10. Orlor R1, Hersche O, Helfet DL, Mayo KA, Ward T, Ganz R.. Avascular femur head necrosis as severe complication after femoral intramedullary nailing in children and adolescents. *Unfallchirurg* 1998;101:495-9.
11. Kaiser MM, Stratmann C, Zachert G, Schulze-Hessing M, Gros N, Eggert R, et al.. Modification of elastic stable intramedullary nailing with a 3rd nail in a femoral spiral fracture model - results of biomechanical testing and a prospective clinical study. *BMC Musculoskelet Disord*. 2014;15:3.

12. Hassan MA, Salama FH, Elshora SA, Safy MA. Treatment of femur fractures in children using elastic stable intramedullary nailing. *Egyptian Orthopedic Journal* 2015;50:127–131.
13. Baldwin K, Hsu JE, Wenger DR, Hosalkar HS. Treatment of femur fractures in school-aged children using elastic stable intramedullary nailing: a systematic review.. *J Paeds Orthop*; 2011;20(5)303-8
14. Ligier JN, Metaizeau JP, Prevot J, Lascombes P. Elastic stable intramedullary nailing of femoral shaft fractures in children. *J Bone Joint Surg [Br]* 1988;70-B:74-7.
15. Narayanan UG. Elastic stable (flexible) intramedullary nailing of paediatric femoral fractures. *COA Bulletin* 2003. [www.coa-aco.org/Articles/Publications/Scientific](http://www.coa-aco.org/Articles/Publications/Scientific).
16. Gulati D, Aggarwal A, Singh AP. Complications of Titanium and Stainless Steel Elastic Nail Fixation of Pediatric Femoral Fractures. *J Bone Joint Surg Am.* 2009;91(8):2040-41.
17. Metaizeau JP, Stable elastic intramedullary nailing for fractures of the femur in children. *J Bone Joint Surg [Br]* 2004;86-B:954-7.