

## Outcome of facet joint steroid injection in combination with lignocaine in chronic low back ache.

Aimal Sattar, M. Ayaz Khan, Wali Muhammad, Ahmad Zeb

### ABSTRACT

**Objective:** To determine the effectiveness of facet joint steroid injection in combination with lignocaine in chronic low back ache by measuring the reduction of pain intensity.

**Methods:** This Descriptive study was conducted at the Department of Orthopedic and Trauma Khyber Teaching Hospital Peshawar from 1/02/2018 to 31/07/2018. All patients with chronic low back ache (for three months or more) meeting the inclusion criteria were included. Pre pain was assessed using visual analog scale (VAS). Under image intensifier each facet joint was infiltrated with a mixture containing 10 mg of steroid and 2 ml of 1% lidocaine. Follow ups were done at six weeks time and improvement was measured using the same grading system (VAS) to confirm the effectiveness of the procedure. Treatment was considered effective if the patient score below 4 on VAS after treatment with facet joint steroid injection.

**Results:** In our study 145 patients with chronic low back ache were analyzed. The mean age was 56 years with SD  $\pm$  22.91. The percentage of male patients were 52% while 46% were female. Mean duration of low back ache was 8 month with SD  $\pm$  3.37. Facet joint steroid injection was efficacious in 67% patients and was ineffective in 33% patients.

**Conclusion:** Facet joint steroid injection in combination with lignocaine is effective in reducing chronic backache and discomfort to the patients.

**Keywords:** Chronic low back ache, efficacy, facet joint steroid injection.

*This article may be cited as:* KHAN, Aimal Sattar et al. Outcome of Facet Joint Steroid Injection in Combination with Lignocaine in Chronic Low Back Ache.. **Journal of Pakistan Orthopaedic Association**, [S.I.], v. 30, n. 4, p. 138-142, apr. 2019. ISSN 2076-8966. Available at: <http://jpoa.org.pk/index.php/upload/article/view/273>.

### INTRODUCTION

Of all chronic pain disorders, chronic low back ache is the most common.<sup>1</sup> Chronic low back ache is defined as chronic and recurrent pain persistent for more than 3 months as most of the connective tissues heal normally in one half to three months period, unless there is any patho-anatomic instability. Chronic low back ache is the most widely recognized of all spinal, and even endless, pain issues. Any pathology in lumbar spine vertebrae, interarticular joints, sacroiliac joints, tendons, ligaments, muscles, and nerve root dura may prompt pain in the lumbar spine with symptoms of back ache in lumbosacral region and lower limb.

Frequently, the correct reason for the pain can't be found. Proof demonstrate that lumbar facet joint pain represent 30% of cases, sacroiliac joint pain represents under 10% of cases, and diagnostic pain represents 25% of the patients with unending low back pain without disc prolapse or narrowing of the spinal canal.<sup>1</sup>

In a Meta-analysis of available data in regards to the frequency and relationship of persistent pain in the elderly population is 56%.<sup>2</sup> In a cross sectional investigation in Korea the existence time of low back ache in patients with high blood pressure was 54.4%.<sup>3</sup>

Multiple therapeutic interventional techniques for chronic low back ache with reasonable evidence exists.<sup>1</sup> Facet joint injection with steroids in combination with local anesthetic is one of the safe minimally invasive treatments for this purpose.<sup>4</sup> Studies have shown significant improvement in patients, symptoms on numerical rating pain scale (NRS).<sup>5</sup> Intraarticular combination of steroid and lignocaine in facet joint is a treatment modality for low

*Department of Orthopaedics Khyber Teaching Hospital Peshawar.*

*Correspondence to: Dr. Aimal Sattar Khan*

*Email: [drimalsattar@gmail.com](mailto:drimalsattar@gmail.com)*

back ache that originates from facet joint and had adequate immediate and constant effect.<sup>6</sup> In lumbar spinal stenosis patients facet joint injection is an effective treatment having 59.5% efficacy.<sup>7</sup>

The present study will help in establishing local statistics on effectiveness of steroid in combination with lignocaine in our population as different authors have reported different results and also no single study has been conducted in our community on outcome of facet joint steroid injection in combination with local anesthetic for chronic low back ache. This will help us in reducing the cost of treatment and frequent Outpatient Department (OPD) visits associated with chronic low back ache. The results of this study will be disseminated to other health professionals and suggestions will be given for rational use for steroid injection for chronic low back ache.

**METHODS**

This descriptive study was conducted in the Department of Orthopedic and Trauma Khyber Teaching Hospital Peshawar from 1/02/2018 to 31/07/2018. Pain which occurs in an area with boundaries between the lower rib and the crease of the buttocks is low back ache persistent for three months or more or, despite treatment of back ache having known pathology. Patients of either gender with age ranged 18-70 years having back pain and poor response to NSAIDS and persistent for more than three months were included in the study. Pregnant ladies, low back ache secondary to fracture vertebrae, tumor, inflammatory disorder, infection, any disease that need immediate surgical intervention were not included in our study. Prior permission of the study from Ethical Review Board was taken. Informed consent was taken from all the participants of the study. Non probability consecutive sampling technique was used for sampling.

The sample size of our study was 145, using available evidence of 59.5% excellent outcome of facet joint injection for chronic low back ache in literature, 95% confidence interval and 8% error margin and formula adopted was WHO health statistic sample size formula.

Measurement tool used for outcome of pain relief was visual analogue scale (VAS). The patients were asked to rate their pain intensity on a 10-point scale before and after treatment at specific intervals. VAS scale 0 indicates no pain and 10 indicate Severe pain within 1 week, interpreted as:

0	123	456	78910
---	-----	-----	-------

None      Mild              Moderate              Severe

Treatment was considered effective if the patient score below 4 on VAS after treatment with facet joint steroid.

In all the included subjects clinical assessment including history and clinical examination and radiograph of the affected site and explanation of the procedure itself. They were admitted to Orthopaedic and Trauma unit, Khyber Teaching Hospital.

Prior to the procedure the patients were assessed using visual analog scale (VAS) for grading of low back pain. Following up were done at six weeks, time and improvement was measured using the same grading system to confirm the effectiveness of the procedure.

Injection was administered under image intensifier. Patient position was 45 degree prone with soft padding under abdomen. After facet joint is identified, needle is advanced under image guidance till bone is felt under aseptic conditions.

Each facet joint was be infiltrated with a mixture containing 10 mg of steroid and 2 ml of 1% lidocaine.

All information was recorded in a specially design proforma. Strict exclusion criteria was followed in order to control study bias and confounders. All the procedures and follow up was conducted by a single experienced surgeon (fellow of CPSP).

All data was stored and analyzed using SPSS version 17. Quantitative variables like age, duration of back ache was analyzed using mean along with standard deviation (before and after treatments). Qualitative variable like gender, pain intensity, efficacy were analyzed using frequency and percentage. In order to assess the effect of age, duration of LBP, and gender on efficacy, data was stratified with respect to age, gender, duration of back ache, pain before treatment. Chi-square test was applied after stratification. P-value was kept ≤0.05 as significant. Results were expressed in form of figures, charts and tables.

**RESULTS**

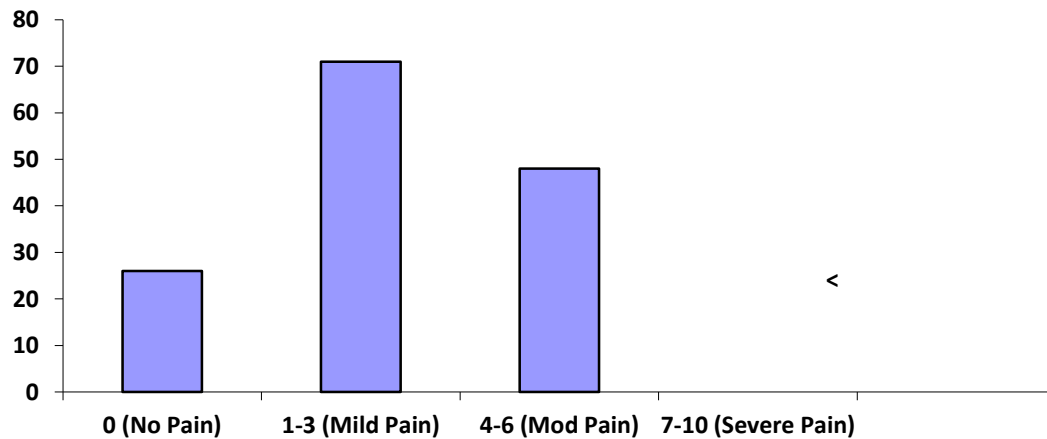
Study was performed in the Orthopaedic and trauma unit, Khyber Teaching Hospital. Total number of patients were 145. Distribution of 145 patients in age ranges were 28(19%) patients were between 20-40 years, 78(54%) patients were between 41-60 years and 39(27%) patients were between 61-70 years. Average age was 56 years with SD ± 22.91. Gender distribution among 145 patients was analyzed as 75(52%) male and

70(48%) female. Majority(58%,n=84) of the patients had low back pain ≤ 10 months while 61(42%) patients had low back pain >10 months. Mean duration of low back pain was 8 month with SD ± 3.37.

About 99(68%) patients had moderate pain with VAS pain score (4-6) while 46(32%) patients had severe pain with VAS pain score (7-10) before the injection. Mean pre injection pain score was 7 with SD ± 3.82. VAS pain score and severity of low back pain after the treatment showed that 26(18%) patients had no pain with VAS pain score (0), 71(49%) patients had mild pain

with VAS pain score (1-3) and 48(33%) patients had moderate pain with VAS pain score (4-6). Mean post injection pain score was 3 with SD ± 1.97. (Graph 1) Facet joint steroid injection effectiveness was observed in 97(67%) patients and ineffective in 48(33%) patients.

Age, gender and duration of low back ache stratification with respect to effectiveness is given in tables(table 1,2 and 3 respectively).No statistically significance was noted by analyzing these three variables(P values 0.9121, 0.9514 and 0.9449 respectively).



Graph 1: Graph showing post injection pain score(VAS)

Table 1: Age wise stratification of efficacy.

EFFICACY	20-40 years	41-60 years	61-70 years	Total
Effective	18	52	27	97
Ineffective	10	26	12	48
Total	28	78	39	145

Table 2: Gender wise stratification of efficacy.

EFFICACY	Male	Female	Total
Effective	50	47	97
Not effective	25	23	48
Total	75	70	145

Table 3: Duration wise stratification of efficacy.

EFFICACY	≤ 10 months	>10 months	Total
Effective	56	41	97
Not effective	28	20	48
Total	84	61	145

## DISCUSSION

Chronic low back ache is the most frequent of all spinal problems, and even persistent pain problems. Any pathology in lumbar spine, articular facet joints, sacroiliac joints, ligaments, fascia, muscles, and nerve root dura may lead to pain in the lumbar spine with resulting symptoms of low back pain and pain radiating to lower limb. Often, the exact cause of the pain cannot be found. In literature the frequency of patients with facet pain is 30%, sacroiliac joint pain less than 10%, and that of diagnostic pain 25% of the patients with chronic low back ache without disc prolapse or narrowing of the spinal canal.<sup>9</sup>

Our study shows that mean age was 56 years with SD ± 22.91. 52% patients were male while forty-eight percent patients were female. Mean duration of low back ache was 8 month with SD ± 3.37. More over facet joint steroid injection in combination with lignocaine

was efficacious in 67% patients and was not effective in 33% patients.

Similar results were observed in another study conducted by Hwang<sup>12</sup> that included 42 enrolled patients (male/female = 14/28; mean age, 58 years; range, 41-88 years), 25 patients (59.5 %) were labelled as having favorable outcome while 17 patients were labelled unfavorable outcome. Eighteen (72 %) of the 25 patients with mild-to-moderate spinal canal narrowing had effective relief, and 7 of the 17 (41.2 %) patients with severe central canal narrowing had effective relief.

Similarly, in Shah<sup>13</sup> research study, 20 to 70 years age group had no relief of low back ache with conventional oral analgesic and exercises. The facet joint were injected under image intensifier. Pain was analyzed using Mac nab and Prolo pain assessment criteria. Additional data, including short-term effect (> 1 week) and medium-term effect (at 3 months), were collected by a structured review interview. Results of different radiological investigations done in these patients were noted. Low back ache was relieved in 37 patients (74%) and 28 (56%) patients immediately (7 days) and short term (one and half months) respectively, while pain was not relieved 16 patients (33%) at medium term (after 12 weeks). Injection of steroid and lignocaine in facet joint was found effective in medium term in 33.3% of patients with chronic low back ache and is alternative to non operative treatment.

Lilius<sup>14</sup> found tantamount impacts after placebo (saline) and methyl prednisolone injection. Even small amount of injection was too large in volume to remain confined in small facet joint. In past large volume of injection were used with similar results. Leakage of medication can leads to confounding results like root block and its branches. However, blocking facet joint provide relief of pain in patients resulting in pain relief (50% pain decrease in one third of patients) in patients with chronic lower back ache and can be applied without any side effects.

We recommend further larger scale randomized controlled trial on fact injections to document strong positive evidence in favor of our results.

## CONCLUSION

Fact joint steroid injection in combination with lignocaine is effective in reducing chronic backache and discomfort to the patients. We recommend this treatment option for all patients with chronic low back

ache not responding to conventional methods of pain relief.

## REFERENCES

1. Manchikanti L, Abdi S, Atluri S, Benyamin RM, Boswell MV, Buenaventura RM et al. An update of comprehensive evidence-based guidelines for interventional techniques in chronic spinal pain. Part II: guidance and recommendations. *Pain Physician*. 2013 Apr;16(2 Suppl):S49-283.
2. Jackson T, Thomas S, Stabile V, Han X, Shotwell M, McQueen K. Prevalence of chronic pain in low-income and middle-income countries: a systematic review and meta-analysis. *Lancet*. 2015 Apr 27;385 Suppl 2:S10.
3. Bae YH, Shin JS, Lee J, Kim MR, Park KB, Cho JH, Ha IH. Association between hypertension and the prevalence of low back pain and osteoarthritis in Koreans: a cross-sectional study. *PLoS One*. 2015 Sep 22;10(9):6-1
4. Chambers H. Physiotherapy and lumbar facet joint injections as a combination treatment for chronic low back pain. A narrative review of lumbar facet joint injections, lumbar spinal mobilizations, soft tissue massage and lower back mobility exercises. *Musculoskeletal Care* 2013;11(2):106-20
5. Kremer S, Pfirrmann CW, Hodler J, Peterson CK. Imaging-guided lumbar facet injections: is there a difference in outcomes between low back pain patients who remember to return a postal questionnaire and those who do not?, *Insights Imaging*. 2012 Aug;3(4):411-8.
6. Lakemeier S, Lind M, Schultz W, Fuchs-Winkelmann S, Timmesfeld N, Foelsch C, et al. A comparison of intraarticular lumbar facet joint steroid injections and lumbar facet joint radiofrequency denervation in the treatment of low back pain: a randomized, controlled, double-blind trial. *Anesth Analg*. 2013 Jul;117(1):228-35.
7. Hwang SY, Lee JW, Lee GY, Kang HS. Lumbar facet joint injection: feasibility as an alternative method in high-risk patients. *Eur Radiol*. 2013 Nov;23(11):3153-60.
8. National Center for Health Statistics :Limitations of activity due to chronic conditions, United States. Series 10, No.111. 1974.
9. National Center for Health Statistics (1982): Surgical operations in short stay hospitals by diagnosis, United States. 1978. Series 13, No.61.

10. Weinstein SM, Herring SA, Derby R. Contemporary concepts in spine care: epidural steroid injections. *Spine* 1995;20:1842-6.
11. Cyteval C, Fescquet N, Thomas E, Decoux E, Blotman F, Taourel P. Predictive factors of efficacy of periradicular corticosteroid injections for lumbar radiculopathy. *AJNR Am J Neuroradiol* 2006 May;27(5):978-82.
12. Hwang SY, Lee JW, Lee GY, Kang HS. Lumbar facet joint injection: feasibility as an alternative method in high-risk patients. *Eur Radiol.* 2013 Nov;23(11):3153-60.
13. Shah DBA, Askar Z, Israr A, Gillani UH Evaluation of outcome of facet joints injections in low back pain. *Pak J Med Science* 2010;26(4):892-896.
14. Lilius G, Harilainen A, Laasonen EM, Myllynen P. Chronic unilateral low-back pain: predictors of outcome of facet joint injections. *Spine* 1990;15:780-2.

### **Authorship and Contribution Declaration**

**Dr. Aimal Sattar**, Conception and design of the study, Data collection & interpretation

**Prof. M Ayaz Khan**, Final approval of the version for publication

**Dr. Wali Muhammad**, Revised the manuscript critically for important intellectual content

**Dr. Ahmad Zeb**, Drafted the manuscript