

# Outcome of High Tibial Osteotomy in Patients with Osteoarthritis Knee.

M. Khurram Habib, Zeeshan Ali Khan

## ABSTRACT

**Objective:** To determine the radiological, functional and anatomical outcome in patients with osteoarthritic knee undergoing high tibial osteotomy.

**Methods:** This descriptive study was conducted in the Orthopedic Departments of District Head Quarter Hospital Faisalabad affiliated with Punjab Medical University Faisalabad from Jan 2016 to March 2018. A total of 40 patients of both genders, between 40-65 years of age having advanced degenerative disease of knee limited to medial compartment of joint. Medial open wedge osteotomy was done and outcome was evaluated after 5 years of surgery in terms of radiological knee mechanics, functional outcome scores and arthroscopic evidence of cartilage regeneration in the medial compartment. A signed written consent was taken from every patient.

**Results:** There was a female predominance (1:4 male female ratio). The mean age of the patients was  $53.2 \pm 6.9$  years. The values of the radiographic parameters significantly changed from pre-operative condition after high tibial osteotomy; MTFA ( $-8.1 \pm 1.2^\circ$  vs.  $2.5 \pm 1.2^\circ$ ;  $p$ -value  $< 0.0001$ ), TPI ( $5.3 \pm 1.1^\circ$  vs.  $3.4 \pm 1.1^\circ$ ;  $p$ -value  $< 0.0001$ ), G-KJLO ( $0.3 \pm 0.1^\circ$  vs.  $4.6 \pm 1.5^\circ$ ;  $p$ -value  $< 0.0001$ ) and G-AJLO ( $8.3 \pm 3.2^\circ$  vs.  $2.3 \pm 1.7^\circ$ ;  $p$ -value  $< 0.0001$ ). There was significant improvement in patient's functional status; KOOS-ADL score ( $45.5 \pm 7.8$  vs.  $73.7 \pm 8.6$ ;  $p$ -value  $< 0.0001$ ), IKDC score ( $42.4 \pm 6.9$  vs.  $68.5 \pm 12.7$ ;  $p$ -value  $< 0.0001$ ), IKS score ( $149.4 \pm 11.9$  vs.  $179.4 \pm 10.2$ ;  $p$ -value  $< 0.0001$ ), KSS ( $54.2 \pm 5.6$  vs.  $69.7 \pm 12.7$ ;  $p$ -value  $< 0.0001$ ) and HSS ( $50.8 \pm 3.3$  vs.  $64.8 \pm 10.7$ ;  $p$ -value  $< 0.0001$ ). 42.5% patients showed excellent regeneration of femoral and 30.0% patients showed excellent regeneration of tibial cartilage in the medial compartment.

**Conclusion:** By significantly alternating the knee biomechanics, high tibial osteotomy was found to unload the medial compartment leading to regeneration of the articular cartilage and dramatic improvement in the symptoms and quality of life of these patients. It is therefore recommended in the management of patients with arthritic changes limited to medial compartment only.

**Keywords:** Osteoarthritis Knee, High Tibial Osteotomy, Functional Outcome

*This article may be cited as:* HABIB, Muhammad Khurram; KHAN, Zeeshan Ali. Outcome of High Tibial Osteotomy in Patients with Osteoarthritis Knee. *Journal of Pakistan Orthopaedic Association*, [S.l.], v. 30, n. 4, p. 162-167, apr. 2019. ISSN 2076-8966. Available at: <http://jpoa.org.pk/index.php/upload/article/view/278>.

## INTRODUCTION

Osteoarthritis (OA), the most prevalent joint disease, affects about 18-20% of women and 8-10% of men over 60 years of age<sup>1,2</sup>. Although osteoarthritis may affect any joint, the hip and knee joints are more frequently involved<sup>1</sup>. OA affects the entire joint including synovium, subchondral bone and articular cartilage and leads to joint stiffness, pain, crepitus, reduced range of movement, limited function and varying degrees of local inflammation<sup>3,4</sup>. Osteoarthritis

is a chronic condition and currently there is no cure for it<sup>1</sup>. The management of knee osteoarthritis can be grouped into first, second, and third line of treatment<sup>5-7</sup>. First line of treatment comprises of patient's education, physiotherapy, and weight reduction<sup>7</sup> while the second line of treatment consists of drug therapy for the control of pain, assistive devices for activities of daily living, along with the first line of treatment<sup>7</sup>. Third line of treatment comprises surgery where total knee arthroplasty (TKA) is the treatment of choice for end-stage arthritic joint<sup>5-7</sup>.

Debeyre and Patte in 1951<sup>8</sup> first described high tibial opening wedge osteotomy. High tibial osteotomy was the definitive treatment choice for arthritis knee a decade ago but due to the improved designs of Total knee replacement, Osteotomy losing attention day by

*Department of Orthopaedics, District Head Quarter Hospital, Faisalabad*

*Corresponding Author: M. Khurram Habib*

*Corresponding E-mail: khurramhabibortho@gmail.com*

day especially in older patients.<sup>8,9</sup> Total knee replacement is not considered a good option for osteoarthritis of knee in younger patients as the implant failure is more<sup>10</sup>. The pain subsides after surgery and patient continue usual life style and total knee replacement is delayed<sup>8,9</sup>.

Data on long term outcome of OWHTO is scarce and only few studies have reported outcome after 5 years of surgery<sup>8,9</sup>. Also, there was no such local published material which necessitated the present study to determine the clinical, radiological and anatomical outcome of OWHTO in patients with medial compartment osteoarthritis of knee.

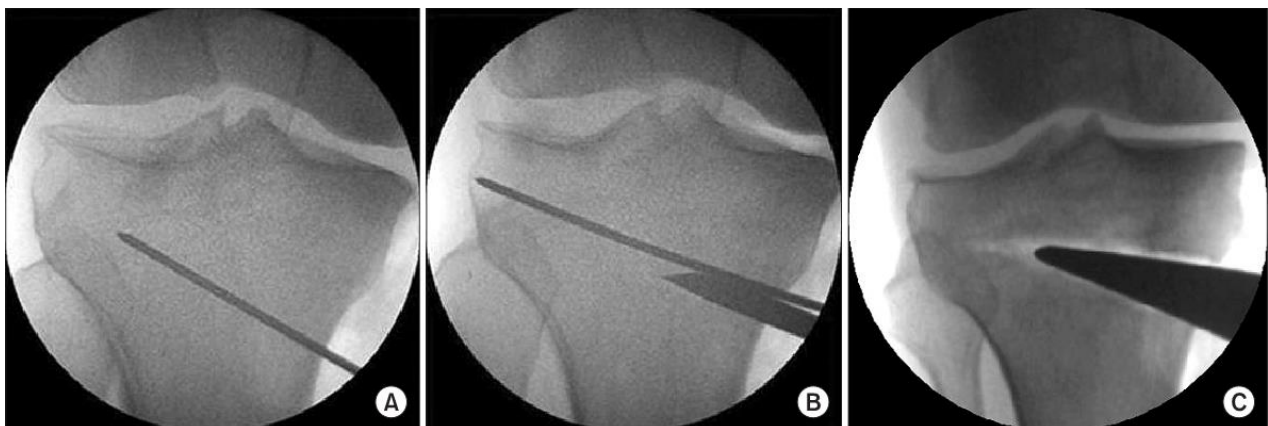In our muslim society since people prefer prayers or worship in the standard recommended fashion therefore they are reluctant to knee replacement. More over the economic feasibility of knee replacement prosthesis and labouring profession of most of our population, high tibial osteotomy is a better option for this set of population. It preserves patients own bone stuck and knee replacement can be done successfully at later stages when arthritis involves lateral compartment.

## METHODS

The present study was a descriptive case series carried at the Orthopedic Departments of District Head Quarter Hospital Faisalabad affiliated with Punjab Medical University Faisalabad from Jan 2016 to March 2018. Sample size of 40 cases was calculated with 95% confidence interval and 80% power of test considering expected mean IKS (International Knee Society score) function score to be  $84 \pm 15.5$  before and  $95 \pm 8.9$  after

high tibial osteotomy in patients with medial compartment OA knee<sup>11</sup>. Patients of both genders, aged between 40-65 years having advanced degenerative disease of knee (grade 3 or 4 on radiological assessment according to Kellgren and Lawrence) limited to medial compartment of joint, varus angulation of more than  $4^\circ$ , and arthroscopic full-thickness articular cartilage deficiencies in the medial compartment were included in this study. Patients  $\geq 65$  years of age, with secondary arthritis (after trauma, infection and ligamentous instability of joint), advanced patellofemoral arthritis, ROM  $< 90^\circ$ , flexion contracture  $\geq 15^\circ$ , joint instability and lateral tibial thrust  $\geq 1$  cm and rheumatoid arthritis were not included in the study.

The study protocols were approved by the Ethical Review Board (ERB) of the hospital and informed consent was taken from all the participants. The procedure was performed through a standardized technique by the senior surgeon under tourniquet control. The surgery was performed in supine position under image intensifier through 5 cm incision. Pre operative antibiotics were given to all the patients and tourniquet was used. Two guide wires were placed 3.5-4 cm below the medial joint line passed diagonally 1 cm underneath the lateral margin of the tibia (Fig. 1A). The appropriate location was confirmed with fluoroscope. A tibial osteotomy was then completed directly underneath the guide wires with the help of a saw (Fig. 1B). Afterward, a regulated wedge was introduced till the osteotomy was opened to the preferred extent (Fig. 1C). Once the anticipated degree of correction was attained, internal fixation was performed with a metal plate.



**Figure 1:** OWHTO. (A) Guide wire is placed (B) Osteotomy is done with a saw. (C) The medial tibia is released with a wedge.

Dynamic Knee brace was applied and joint exercises and partial weight bearing was started. At 6 to 12 weeks weight bearing is increased, while the knee brace was cast-off. Maintenance of correction and bone union was evaluated through X-rays on a regular interval. Outcome was assessed radiologically; by change in mechanical tibiofemoral angle (MTFA), tibial plateau inclination (TPI), knee joint line orientation relative to the ground (G-KJLO) and ankle joint line orientation relative to the ground (G-AJLO) angles, functionally; by improvement in Knee-Injury and Osteoarthritis Outcome Score (KOOS), International Knee Documentation Committee (IKDC) score, International Knee Society score (IKS), Hospital for Special Surgery (HSS) knee scores and Knee Society Score (KSS) and anatomically by arthroscopic evidence

of regeneration of articular cartilage in the medial compartment graded as excellent (100%), good ( $\geq 50\%$ ) and poor ( $< 50\%$ ) after 5 years of surgery.

Data analysis was done through SPSS version 22. Paired sample t-test was used to compare mean change in numerical variables before and after treatment.

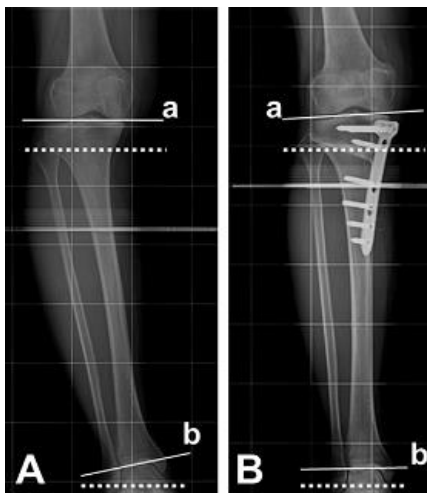
**RESULTS**

Our patients had age ranged from 40 years to 65 years with a mean of  $53.2 \pm 6.9$  years. There were 8 (20.0%) male and 32 (80.0%) female patients in the study group with a male to female ratio of 1:4.

**Table 1:** Comparison of various outcome measures before and after osteotomy

| Outcome                     | Pre-Operative    | Post-Operative   | P value  |
|-----------------------------|------------------|------------------|----------|
| <b>Radiological Outcome</b> |                  |                  |          |
| MTFA (degree)               | -8.1 $\pm$ 1.2   | 2.5 $\pm$ 1.2    | <0.0001* |
| TPI (degree)                | 5.3 $\pm$ 1.1    | 3.4 $\pm$ 1.1    | <0.0001* |
| G-KJLO (degree)             | 0.3 $\pm$ 0.1    | 4.6 $\pm$ 1.5    | <0.0001* |
| G-AJLO (degree)             | 8.3 $\pm$ 3.2    | 2.3 $\pm$ 1.7    | <0.0001* |
| <b>Functional Outcome</b>   |                  |                  |          |
| KOOS-ADL score              | 45.5 $\pm$ 7.8   | 73.7 $\pm$ 8.6   | <0.0001* |
| IKDC score                  | 42.4 $\pm$ 6.9   | 68.5 $\pm$ 12.7  | <0.0001* |
| IKS score                   | 149.4 $\pm$ 11.9 | 179.4 $\pm$ 10.2 | <0.0001* |
| KSS                         | 54.2 $\pm$ 5.6   | 69.7 $\pm$ 12.7  | <0.0001* |
| HSS                         | 50.8 $\pm$ 3.3   | 64.8 $\pm$ 10.7  | <0.0001* |

Paired sample t-test, \* observed difference was statistically significant



**Figure 2:** X-Ray describing changes of the KJLO and the AJLO comparative to the ground.

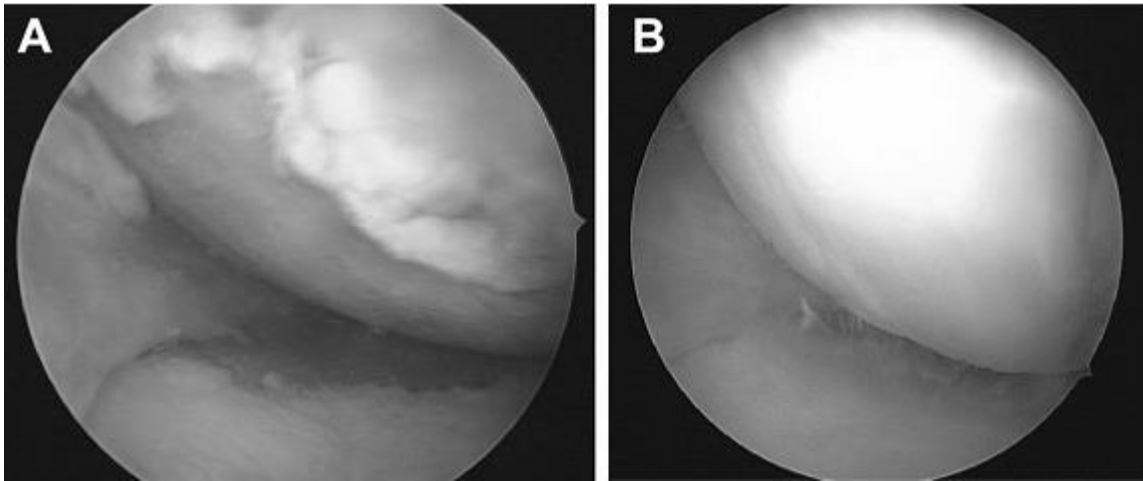
**Table 2:** Regeneration of articular cartilage

| Characteristics | Femoral    | Tibial     |
|-----------------|------------|------------|
| Excellent       | 17 (42.5%) | 12 (30.0%) |
| Good            | 18 (45.0%) | 20 (50.0%) |
| Poor            | 5 (12.5%)  | 8 (20.0%)  |

The radiology of joint changed significantly from pre osteotomy status. (Table 1, Fig. 2). We found that the decrease of the AJLO relative to the ground backed the relative small change of the knee joint line orientation; the sum of changes in those two alignments came close to the overall change of the mechanical tibiofemoral angle after high tibial osteotomy. Various scores assessing functional outcome improved significantly than pre-operative values as shown in Table 1. Arthroscopic evaluation

revealed marked improvement in femoral and tibial articular cartilage in the medial compartment owing to

unloading effect of osteotomy and regeneration of fibrocartilage (Table 2, Figure 3).



**Figure 3:** Medial compartment articular cartilage (A) Before Surgery and (B) After Surgery.

## DISCUSSION

Osteotomy for the osteoarthritis of the knee delay total knee replacement (TKR) specially in younger population.<sup>12</sup> Though the use of high tibial osteotomy has dropped lately due to the development of TKA, it is undeniable that proper patient choice, accurate surgical preparation, and appropriate surgical technique can provide promising outcomes of HTO<sup>13,14</sup>. Our objective of conducting this study was to assess post osteotomy radiological, functional and anatomical outcome of in carefully selected cohort of patients with medial compartment OA knee.

Our findings are consistent with already published literature where Lee<sup>15</sup> reported similar results osteotomy; MTFA ( $-8.3 \pm 2.3^\circ$  vs.  $2.5 \pm 2.2^\circ$ ;  $p$ -value  $< 0.0001$ ), TPI ( $5.6 \pm 2.1^\circ$  vs.  $3.4 \pm 3.0^\circ$ ;  $p$ -value  $< 0.0001$ ), G-KJLO ( $0.3 \pm 2.1^\circ$  vs.  $4.4 \pm 2.6^\circ$ ;  $p$ -value  $< 0.0001$ ) and G-AJLO ( $8.8 \pm 3.2^\circ$  vs.  $2.0 \pm 3.9^\circ$ ;  $p$ -value  $< 0.0001$ ). In another similar study Schuster reported that International Knee Documentation Committee score improved significantly after high tibial osteotomy<sup>16</sup> ( $44 \pm 11$  pre-operatively to  $70 \pm 13$  post-operatively;  $p$ -value  $< 0.001$ ) in line with the present study. Schuster also reported similar frequency of excellent cartilage regeneration on femoral (40.9%) and tibial (29.4%) condyles in the medial compartment of the joint<sup>16</sup>. Polat<sup>17</sup> in a similar study reported similar significant improvement in Knee Society Score ( $56.3 \pm 13.4$  vs.  $70.3 \pm 14.9$ ;  $p$ -value  $\leq 0.05$ ) and the Hospital for Special Surgery score ( $51.3 \pm 9.7$  vs.  $64.7 \pm 13.5$ ;  $p$ -value  $\leq 0.05$ ). Similar improvement in

Knee-Injury and Osteoarthritis Outcome (KOOS)-activities of daily living score ( $48.3 \pm 20.1$  vs.  $78.5 \pm 19.8$ ;  $p$ -value  $\leq 0.05$ ) and International Knee Society score ( $154 \pm 26.1$  vs.  $185 \pm 12.1$ ;  $p$ -value  $\leq 0.05$ ) has been reported by Roos and Brosset<sup>11,18</sup> respectively.

The present study is first of its kind in local population and adds to the already published international research on the topic. The strengths of the present study are longer follow-up of 5 years and arthroscopic, radiological and functional evaluation of patient's outcome. In the light of this evidence, it can be advocated that patients with OA knee who are particularly young with changes limited to medial compartment of the joint should be offered high tibial osteotomy to improve the patient condition while buying some time before the patient needs TKR.

A very strong limitation to the present study was that we only performed medial open wedge osteotomy and didn't compare the outcome between medial open wedge and lateral closing wedge osteotomy which would have further helped in the selection of appropriate approach and implant. Such a study is highly recommended in future research.

## CONCLUSION

By significantly alternating the knee biomechanics, high tibial osteotomy was found to unload the medial compartment leading to regeneration of the articular cartilage and dramatic improvement in the symptoms and quality of life of these patients. It is therefore

recommended in the management of patients with arthritic changes limited to medial compartment only.

## REFERENCES

1. Glyn-Jones S, Palmer AJ, Agricola R, Price AJ, Vincent TL, Weinans H, et al. Osteoarthritis. *Lancet* 2015;386(9991):376-87. doi: 10.1016/S0140-6736(14)60802-3.
2. Neogi T. The epidemiology and impact of pain in osteoarthritis. *Osteoarthritis Cartilage* 2013;21(9):1145-53. doi: 10.1016/j.joca.2013.03.018.
3. Chen D, Shen J, Zhao W, Wang T, Han L, Hamilton JL, et al. Osteoarthritis: toward a comprehensive understanding of pathological mechanism. *Bone Res* 2017;5:16044. doi: 10.1038/boneres.2016.44.
4. Man GS, Mologhianu G. Osteoarthritis pathogenesis - a complex process that involves the entire joint. *J Med Life* 2014;7(1):37-41.
5. Hermann W, Lambova S, Muller-Ladner U. Current treatment options for osteoarthritis. *Curr Rheumatol Rev* 2018;14(2):108-16. doi: 10.2174/1573397113666170829155149.
6. Zhang W, Ouyang H, Dass CR, Xu J. Current research on pharmacologic and regenerative therapies for osteoarthritis. *Bone Res* 2016;4:15040. doi:10.1038/boneres.2015.40.
7. Lespasio MJ, Piuze NS, Husni ME, Muschler GF, Guarino A, Mont MA. Knee osteoarthritis: a primer. *Perm J* 2017;21:16-183. doi: 10.7812/TPP/16-183.
8. Sabzevari S, Ebrahimpour A, Roudi MK, Kachooei AR. High tibial osteotomy: a systematic review and current concept. *Arch Bone Jt Surg* 2016;4(3):204-12.
9. Kyung HS. High tibial osteotomy for medial knee osteoarthritis. *Knee Surg Relat Res* 2016;28(4):253-4. doi: 10.5792/ksrr.16.253.
10. Amoako AO, Pujalte GG. Osteoarthritis in young, active, and athletic individuals. *Clin Med Insights Arthritis Musculoskelet Disord* 2014;7:27-32. doi: 10.4137/CMAMD.S14386.
11. Brosset T, Pasquier G, Migaud H, Gougeon F. Opening wedge high tibial osteotomy performed without filling the defect but with locking plate fixation (TomoFix™) and early weight-bearing: prospective evaluation of bone union, precision and maintenance of correction in 51 cases. *Orthop Traumatol Surg Res* 2011;97(7):705-11. doi: 10.1016/j.otsr.2011.06.011.
12. Bonasia DE, Governale G, Spolaore S, Rossi R, Amendola A. High tibial osteotomy. *Curr Rev Musculoskelet Med* 2014;7(4):292-301. doi: 10.1007/s12178-014-9234-y.
13. Pipino G, Indelli PF, Tigani D, Maffei G, Vaccarisi D. Opening-wedge high tibial osteotomy: a seven - to twelve-year study. *Joints* 2016;4(1):6-11. doi:10.11138/jts/2016.4.1.006.
14. Giuseffi SA, Replogle WH, Shelton WR. Opening-wedge high tibial osteotomy: review of 100 consecutive cases. *Arthroscopy* 2015;31(11):2128-37. doi: 10.1016/j.arthro.2015.04.097.
15. Lee KM, Chang CB, Park MS, Kang SB, Kim TK, Chung CY. Changes of knee joint and ankle joint orientations after high tibial osteotomy. *Osteoarthritis Cartilage* 2015;23(2):232-8. doi: 10.1016/j.joca.2014.11.001.
16. Schuster P, Geßlein M, Schlumberger M, Mayer P, Mayr R, Oremek D, et al. Ten-year results of medial open-wedge high tibial osteotomy and chondral resurfacing in severe medial osteoarthritis and varus malalignment. *Am J Sports Med* 2018;46(6):1362-70. doi: 10.1177/0363546518758016.
17. Polat G, Balci Hİ, Çakmak MF, Demirel M, Şen C, Aşık M. Long-term results and comparison of the three different high tibial osteotomy and fixation techniques in medial compartment arthrosis. *J Orthop Surg Res* 2017;12(1):44. doi: 10.1186/s13018-017-0547-6.
18. Roos EM, W-Dahl A, Toksvig-Larsen S, Lohmander LS. High tibial osteotomy and total knee replacement for knee OA - similar outcomes from the patient's perspective. *Orthop Res Soc* 2017;2017:2463.

## Authorship and Contribution Declaration

**M. Khurram Habib,**

Conception and design, Collected the data, interpreted the data, Drafted the manuscript

**Zeeshan Ali Khan**

Revised the manuscript critically for important intellectual content, final approval of the version for publication