

## Primary Tibial Synovial Sarcoma: Uncommon Tumour on Uncommon Site –Case Reports

Muhammad Muzzammil, Muhammad Saeed Minhas, Anisuddin Bhatti, Adnan Hussain Muhammad Ovais, Abdul Qadir, Ayesha Mughal, Syed Jahanzeb

### ABSTRACT

**Objective:** To report the clinical characteristic of primary tibial synovial sarcoma, in terms of aggressiveness, local spread/ metastasis, surgical procedures and final outcome.

**Methods:** 3 case reports conducted and diagnosed in last 10 years were included and examined clinically as well radiologically. and ultimate surgical procedures performed and post operative follow up were studied and recorded. Patients diagnosed and procedures performed at other centre were excluded. All three patients underwent wide surgical excision and reconstruction with non vascularized fibular graft. Clinical and radiographical follow up of 3 years done to see any recurrence and other complications.

**Results:** three cases of primary tibial synovial sarcoma diagnosed in study period, all of them were female and in teen age, 2 were of 17 years and one 19 years old. One case of 19 years female present with history of 1 year of swelling and pain of leg. Second and third case of 17 years age present with history of 6 and 9 months respectively of mass and pain in leg respectively. All cases were examined, investigated and biopsy done showed synovial sarcoma, followed by Wide local excision done, non-vascularized graft from fibula of opposite leg placed and anti rotatory screw applied in first case and Non-vascularized graft from fibula of opposite leg and fixation with inter-medullary k-wire and buttress T plate done in second and third case. Wound covered with rotational flap in all three cases followed by chemotherapy. No complication or recurrence noted in 3 years follow-up.

**Conclusion:** Primary Synovial sarcoma of bone is rare tumour and rarely occurs at tibia, with a tendency to occur in young adults and chemotherapy sensitivity. These case reports shows good outcome in management of synovial sarcoma with wide local excision and chemotherapy.

**Key Words:** Synovial sarcoma, tibia, chemotherapy, resection, fibular graft.

### INTRODUCTION

Knox firstly named specific neoplasm as synovial sarcoma in 1936 because it was considered to be originated from cells of synovial origin [1]. This tumor is interpreted as a tumour of “uncertain histogenesis” because this name is confusing as numerous cases of synovial sarcoma founded where no synovial tissue exists [2]. Although 20% synovial sarcomas manifest local bone involvement but it is immensely uncommon that synovial sarcoma found to be primary bone tumor origin [3].

Morphologically synovial sarcoma is a well defined tumour, malignant in nature, accounts for five to ten percent of all tumors of soft tissue origin [4,5,6],

mostly affecting young adults and has a onset of 30 years [7] mean age. Synovial sarcoma usually originates in soft tissue of lower extremities [8]. The greater number of this neoplasm arises close to large joints. Synovial sarcoma also reported to be arising in a diversity of different sites such as in the head, maxillofacial and neck [9], thoracic [10], and abdominal cavities [11]. 20% of synovial sarcoma shows destruction or invading of adjoining bone [3]. The keystone of management in tumor like synovial sarcoma is a wide surgical tumour resection, excision of tumor, pseudocapsule, and a marginal part of adjacent normal tissue [12,13]. Chemotherapy has undetermined part in synovial sarcoma management [12]. Synovial sarcoma found to be chemosensitive in several studies [12,14,15].

Primary synovial sarcoma arising from bone is immensely uncommon<sup>1</sup>. We report this case series of

---

*Department Of Orthopaedics, Jinnah Hospital, Karachi*  
 Correspondence: Muhammad Muzzammil  
 E mail: muzamil.sangani@gmail.com

primary tibial synovial sarcoma, which is also an extremely rare site of primary bony synovial sarcoma.

**METHODS**

These case reports conducted patients diagnosed with tibial synovial sarcoma in last 10 years were included. 3 cases were reported, Clinical and radiographic characteristics were examined, and ultimate surgical procedures done and follow up of the patient were analyzed and recorded. Exclusion criteria include tumours with other diagnosis, inflammatory conditions/ infection or managed in other centres. Patients were examined and diagnosed via OPD, admitted in orthopaedic ward and electively operated. Pre operative counselling done for various surgical issues, operative procedures, graft site and related complications were discussed and informed consent taken.

All patients discussed with oncology department regarding pre and post operative chemotherapy and registered in oncology department. Pros and cons of chemotherapy discussed and consent were taken.

All the surgical procedures done by orthopaedic surgeons with experience of more than five

years. Prophylactic preoperative antibiotics given to all patients, 30-60 mins before surgical procedure. Under standard surgical protocols, operations have done in spinal or general anaesthesia in supine position.

All three patients underwent wide local excision, Non-vascularized graft from fibula of opposite leg placed and anti-rotatory screw applied in first case and Non-vascularized graft from fibula of opposite leg and fixation with inter-medullary k-wire and buttress T plate done in second and third case. Antibiotics post operatively given for 5-7 days.

Follow up of all three patients were done clinically and radiographically, checkups schedule as every month for initial three months, then every three months for one year and then every six months of three years.

**RESULTS**

Three cases of tibial synovial sarcoma diagnosed in study period, all of these were female and in teen age, one 19 years old and 2 were of 17 years.

**Table-I:** Patient details

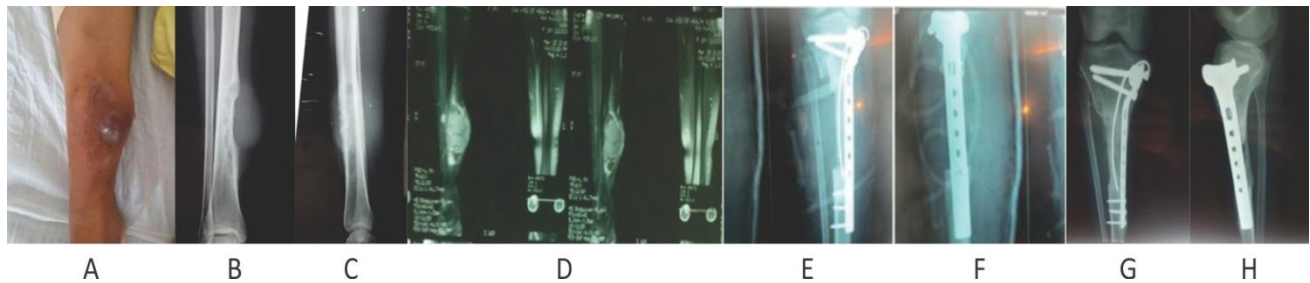
Patient	Age	Gender	Site	Meta-stasis	Chemo-therapy	Procedure	Compli-cation	Follow up
Case 1	19 years	Female	Right tibia	No	Yes	Wide local excision Non-vascularized fibular graft and anti rotatory screw	No	3 years
Case 2	17 years	Female	Right tibiaa	No	Yes	wide margin excisionand non vascularized fibular graft with intermedullary k wire and butteress T plate	No	3.5 years
Case 3	17 years	Female	Left tibia	No	Yes	wide margin excisionand non vascularized fibular graft with intermedullary k wire and butteress T plate	No	3 years

First case of 19 year female patient presents with 1 year history of pain and localized swelling medial aspect of right leg. Pain was gradual in onset localized, non radiating, aggravating with walking relieved with analgesics, Swelling was gradual in onset. On Local

Examination 8\*8 cm swelling on mid of right leg confined to anteriomedial side, black discoloration of skin on central area of swelling. Firm and painful on palpation with no temperature changes.Fixed with skin and underlying tissue. X-ray shows cortical bone

erosion with soft tissue mass. Multiseptated mass lesion with fluids levels seen with erosion of tibial cortex with involvement of medullary cavity. Incisional Biopsy shows synovial cell neoplasm of right lower tibia. Metastatic workup was negative. Wide local excision done 12 cm of tibia with tumor excised. Non vascularized fibular graft from opposite leg placed and

anti rotatory screw applied wound covered with rotational flap. Post OP excisional biopsy shows morphological and immunohistchemical features favor synovial Sarcoma size of lesion 6\*4\*3 cm 0.2cm. Patient sent to oncology department for chemotherapy and call for regular follow up.(table-I)



**Figure-1:** Case number 2 (A) local examination shows swelling anteromedial aspect of right leg with overlying skin discoloration. (B and C) x-ray shows bony erosion soft tissue mass. (D) MRI shows Multiseptated mass lesion with fluids levels seen with erosion of tibial cortex with involvement of medullary cavity. (E and F) post operative x-ray after wide local excision with fibular graft fixed with k-wire and buttress plate. (G and H) 1 year follow up x-ray show good incorporation of graft at both ends.

Second and third case of 17 years age present with history of 6 and 9 months respectively of pain and mass. On examination 6\*6 cms swelling on proximal right leg with no skin or temperature changes, firm in consistency and non tender fixed with underlying tissue in second case and mass of 4\*4 cm on left middle part of leg in third case with similar findings. Both were investigated and open biopsy was performed was diagnostic, showing synovial sarcoma. Tumour excised wide local margins and non vascularized fibular graft from opposite leg placed and fixation with intermedullary k wire and butteress T plate done.(figure-1) Wound covered with rotational flap in both cases, followed by chemotherapy. (table-I)

Mean follow up of all three cases was three years. All patients in follow up period were pain free with adequate incorporation and graft unification at both edges. All three patients revealed good stability and ambulate without support in six months. All three patients get satisfaction in daily routine activities and had good psychological adaptation. In follow up wound infections, graft stress fracture, implant failure and tumour recurrence was not shown in all three cases.

## DISCUSSION

In 1997 synovial sarcoma firstly reported as tumour originated from bone [16]. After this several reports of

diagnosed, bone originated cases of primary synovial sarcoma founded that includes sacral bone [17], tibialdistal part [1,18], mandibular bone [18], tumour involving bones of elbow joint [8,19], and body of sternum [20]. Synovial sarcoma exhibits aggressive nature, due to this management includes combination of surgical excision in form of wide surgical resection to ensure tumour free margins, along with chemotherapy ± radiation therapy. Due to synovial sarcoma's higher local recurrence rates and distant metastasis, clinical and radiological follow up is mandatory for long term periods [21].

On imaging studies, synovial sarcoma represents on Magnetic resonance as intermediate heterogeneous intensity signal on T1 weighted image, high heterogeneous intensity signals on fat suppressed T2 weighted image, and contrast heterogeneous enhancement [1]. Synovial sarcoma divided on microscopic features as monophasic tumour, biphasic tumour and poor/ undifferentiated tumour [2], among them biphasic tumours are the most common variety. Confirmation of tumor like synovial sarcoma can also be established by genetic studies with help of t(X; 18) (p11.2; q11.2) detection [2]. Greater than 90 percent of synovial sarcomas represents with this genetic translocation [22].

A study conducted in late 1950 shows sixty patients with synovial sarcoma managed with marginal resection/ wide marginal resection revealed 63% recurrence of tumour locally [23]. Due to higher recurrence rate showed in this study, only marginal resection without any adjunctive treatment not recommended. Several studies have also revealed obvious recommendation to decrease local recurrence of synovial sarcoma by using irradiation therapy. Lewis et al. revealed 10% of recurrence of synovial sarcoma locally in case series of one hundred twelve patients with extremity tumors [24]. It has been reported that 5 year survival rate of synovial sarcoma is low around 25–50 percent and only survival rate of 10 –15 percent of 10 years [25].

Grossly all these current studies reveal a favorable development in management methods of synovial sarcoma. The short rate of 5 years survival of synovial sarcoma and greater possibility of metastasis distantly still reveal the requirement of the establishment of sufficient systemic management besides encouraging lower figures of recurrence locally. Due to synovial sarcoma's higher recurrence rates locally and distant metastasis, clinical and radiological follow up is mandatory for prolong period of time.

## CONCLUSION

Primary Synovial sarcoma of bone is rare tumour and rarely occurs at tibia, with a tendency to occur in young adults and chemotherapy sensitivity. This small case series shows good outcome in management of synovial sarcoma with wide local excision and chemotherapy.

## REFERENCES

1. S. C. Jung, J. A. Choi, J. H. Chung, J. H. Oh, J. W. Lee, and H. S. Kang, Synovial sarcoma of primary bone origin: a rare case in a rare site with atypical features. *Skeletal Radiol*, 2007 Jan;36(1), 67–71.
2. M. Haldar, R. L. Randall, and M. R. Capecchi, Synovial sarcoma: from genetics to genetic-based animal modelling. *ClinOrthopRelat Res*. 2008 Sep; 466(9): 2156–2167..
3. M. Vliet, M. Klien, G. P. Krestin and C. F. Dijke, Softtissue sarcomas at a glance: clinical, histological, and MR imaging features of malignant extremity soft tissue tumors. *EurRadiol*. 2009 Jun;19(6):1499-511. doi: 10.1007/s00330-008-1292-3.
4. Kransdorf MJ: Malignant soft-tissue tumors in a large referral population: distribution of diagnoses by age, sex, and location. *AJR, Am J Roentgenol* 1995 Jan;164(1): 129–34.
5. Leader M, Patel J, Collins M, Kristin H. Synovial sarcomas. True carcinosarcomas? *Cancer* 1987 Jun;59(12): 2096–8.
6. Weiss SW, Goldblum JR, Enzinger FM: *Enzinger and Weiss's Soft Tissue Tumors*. St. Louis, Mosby Ed 4 2001 pp xiv, 1622..
7. B.W. Scheithauer, A.I. Silva, K. Kattner, J. Seibly, A.M. Oliveira, K. Kovacs, Synovial sarcoma of the sellar region. *NeuroOncol*. 2007 Oct; 9(4): 454–459. doi: 10.1215/15228517-2007-029.
8. P. O'Donnell, T. C. Diss, J. Whelan, and A. M. Flanagan. Synovial sarcoma with radiological appearances of primitive neuroectodermal tumour/Ewing sarcoma: differentiation by molecular genetic studies. *Skeletal Radiolo*, 2006 Apr;35(4), 233–239.
9. G. A. Barkan and A. K. El-Naggar, Primary synovial sarcoma of the parotid gland, *Ann DiagnPathol*, 2004 Aug;8(4), 233–236.
10. K. Anand, A. Khanna, S. K. Sinha, U. Mukherjee, J. S. Walia, A. N. Singh. Pericardial synovial sarcoma, *Clinical Oncology*, 2003. 15(4) 186–188.
11. Fisher, A. L. Folpe, H. Hashimoto, and S. W. Weiss. Intraabdominal synovial sarcoma: a clinicopathological study. *Histopathology*. 2004 Sep;45(3):245-53.
12. Eilber FC, Dry SM. Diagnosis and management of synovial sarcoma. *J SurgOncol* 2008 Mar;97(4): 314–20.
13. Bernhard M. Speth, Andreas H. Krieg, Andre Kaelin, G. Ulrich Exner, Louis Guillou, Arthur von Hochstetter. et al. Synovial sarcoma in patients under 20 years of age: a multicenter study with a minimum follow-up of 10 years. *J Child Orthop* 2011 Oct;5(5): 335–42.
14. Spillane AJ, A'Hern R, Judson IR, Fisher C, Thomas JM. Synovial sarcoma: a clinicopathologic, staging, and prognostic assessment. *J ClinOncol* 2000 Nov;18(22): 3794–803.
15. Wolden SL. Radiation therapy for non-rhabdomyosarcoma soft tissue sarcomas in adolescents and young adults. *J PediatrHematolOncol* 2005 Apr;27(4): 212.
16. I.J. Cohen, J. Issakov, S. Avigadetal. Synovial sarcoma of bone delineated by spectral karyotyping. *Lancet*. 1997 Dec 6;350(9092):1679-80.

17. C. Sar and L. Eralp. Surgical treatment of primary tumors of the sacrum. *Arch Orthop Trauma Surg.* 2002 Apr;122(3):148-55. S. P. Scully, H. T. Temple, and J. M. Harrelson. Synovial sarcoma of the foot and ankle. *ClinOrthopRelat Res.* 1999 Jul;(364):220-6.
18. W. M. Tilakaratne, Synovial sarcoma of the mandible. *J Res Med Sci.* 2012 Nov; 17(11): 1082–1085.
19. H. Hiraga, T. Nojima, K. Isu, K. Yamashiro, S. Yamawaki, K. Nagashima. Histological and molecular evidence of synovial sarcoma of bone: a case report. *J Bone Joint Surg Am.* 1999 Apr;81(4):558-63.
20. Nakajo M1, Ohkubo K, Nandate T, Shirahama H, Yanagi M, Anraku M. et al., Primary synovial sarcoma of the sternum: computed tomography and magnetic resonance imaging findings. *Radiat Med.* 2005 May;23(3):208-12.
21. Fritz C. Eilber, Murray F. Brennan, Frederick R. Eilber, Jeffery J. Eckardt, Stephen R. Grobmyer, Elyn Riedel, MA, et al. Chemotherapy is associated with improved survival in adult patients with primary extremity synovial sarcoma. *Ann Surg.* 2007 Jul; 246(1): 105–113.
22. R. Jeganathan, R. Davis, L. Wilson, J. McGuigan, and P. Sidhu. Primary mediastinal synovial sarcoma. *Ulster Med J.* 2007 May; 76(2): 109–111.
23. G. T. Pack and I. M. Ariel, Synovial sarcoma (malignant synovioma). A report of 60 cases, *Surgery.* 1950 Dec;28(6):1047-84.
24. Lewis JJ1, Antonescu CR, Leung DH, Blumberg D, Healey JH, Woodruff JM. et al. Synovial sarcoma: a multivariate analysis of prognostic factors in 112 patients with primary localized tumors of the extremity. *J ClinOncol.* 2000 May;18(10):2087-94.
25. W. M. Tilakaratne. Synovial sarcoma of the mandible. *J Oral Pathol Med.* 2006 Jan;35(1):61-3.