

Outcome of Max Page Muscle Sliding Operation for the Treatment of Moderate Volkmann's Ischemic Contracture of the Forearm

Assad Ullah Jan,¹ Tehseen Ahmad Cheema,² Wahid Buksh,³ Muhammad Shafiq,⁴ Baqir Hussain Turi,⁵ Farman Ullah.⁶

¹Senior Registrar Khalifa Gul Nawaz Hospital MTI Bannu

²Professor Emeritus National Orthopaedic Hospital Bahawalpur

³Assistant Professor Makran Medical College Turbat

⁴Associate professor Orthopaedics Gomal Medical College DI Khan

^{5,6}Hayat Abad Medical Complex Peshawar

Authorship and contribution

Declaration: Each author of this article fulfilled ALL 4 Criteria of Authorship:

1. Conception and design or acquisition of data, or analysis & interpretation of data.
2. Drafting the manuscript or revising it critically for important intellectual content.
3. Final approval of the version for publication.
4. All authors agree to be responsible for all aspects of their research work.

Corresponding Author:

Asad Ullah Jan

E-mail:asadjankmcb@gmail.com

ABSTRACT

Objective: To evaluate the functional outcomes of Max Page muscle sliding operation in moderate degree of established Volkmann's ischemic contracture (VOIC) of the forearm.

Methods: This was a single-center descriptive study carried out in the period extending from 20th February 2010 to 20th December 2019 at National Orthopedic Hospital Bahawalpur. All patients of moderate Volkmann's ischemic contracture (VOIC) meeting the inclusion criteria were operated with Max Page muscle sliding operation. Post operatively functional outcome was graded with Sharma and Swamy grading system as good, fair and poor. T-test was applied to document statistically significant improvement ($P < 0.05$) between the pre operative and post operative variables of Sharma and Swamy grading system.

Results: A total of 33 patients with mean age 8.5 ± 4 years (range 5 to 12 years) were operated with Max Page muscle sliding operation. Male children were 20 (60.6%) and female 13 (39.4%). Right forearm VOIC was noted in 19 (57.5%) while left side was involved in 14 (42.4%) children. Mean follow up was 13.09 ± 7.60 months. Post operatively good functional outcome was noted in 25 (75.5%) patients and fair in 8 (24.2%) patients. Preoperative mean sensory score was 1.15 ± 0.38 which improved to 1.66 ± 0.22 ($P < 0.05$) post operatively. Hand grip improved from pre operative mean value of 10.3 ± 5 to 80.3 ± 10 ($P < 0.05$). The dexterity score improved from pre operative 4 ± 1 to post operative 11.3 ± 7 ($P < 0.05$).

Conclusion: Good functional outcomes was achieved in majority of moderate Volkmann's ischemic contractures operated with Max Page muscle sliding operation. We therefore recommend Max Page muscle sliding operation as the operation of first choice to treat moderate VOIC of the forearm.

Keywords: Compartment syndrome, Max Page muscle release, Volkmann's ischemic contracture.

This article may be cited as:

Jan AU, Cheema TA, Buksh W, Shafiq M, Turi BH, Ullah F. Outcome of Max Page Muscle Sliding Operation for the Treatment of Moderate Volkmann's Ischemic Contracture of the Forearm. J Pak Orthop Assoc. 2020;32(3)

INTRODUCTION

Volkmann's ischemic contracture results from ischemic insult to the soft tissue of the limb and was first described by Richard von Volkmann in 1881.¹ He attributed this condition to the disruption of arterial supply due to tight bandage applied to an injured extremity. Later on in 1909, it was reported that that this condition can develop even without application of

a splint or bandage.² Others attributed venous obstruction and arterial spasm as a main cause of this condition.³⁻⁵ VOIC can be caused by any injury resulting in soft tissue swelling in a closed osseofascial compartment.⁶ As a result of this soft swelling the intra-compartmental pressure rises to such an extent that capillary perfusion is compromised. VOIC affects those compartment which are least expandable

and deep flexor compartment of the forearm is often the first and the most commonly involved compartment because of its closed proximity to the bone.⁷ Peripheral nerves in VOIC zone are initially damaged by ischemia and later on by fibrosis of the surrounding muscles.⁸

The treatment of established VOIC includes physiotherapy, splinting, muscle sliding, tendon transfer, neurolysis, fibrotic tissue excision, muscle grafting and osteotomy.⁸ The Max Page muscle slide operation was first described by Page in 1923.⁹ It is the best surgical technique for mild and moderate VOIC as it is easy and can be combine simultaneously with neurolysis of median and ulnar nerve and with tendon transfers for residual functional deficit as a staged surgery.¹⁰ This procedure allows maximum correction of flexion correction without affecting the resting muscle length.¹¹ Excellent functional results of Max Page operation have been reported in the literature.¹²⁻¹⁴

The objective of our study was to evaluate the functional outcomes of Max Page muscle sliding operation in moderate degree of established

Volkman’s ischemic contracture(VOIC) of the forearm.

METHODS

We conducted this descriptive study in National Orthopedic Hospital Bahawalpur from 20th February 2010 to 20th December 2019. All children with established VOIC of more than 6 months duration and of moderate type (Tsuge classification)¹⁴ presented to OPD of our hospital were included in our study. VOIC patients with skin or joint contracture, infection and previously operated children were excluded. The study protocols were approved by the Ethical Committee of our hospital and informed consent of surgery and publication was taken from parents of children. In the included children complete history, physical examination and relevant investigations were carried out and prepared for Max Page slide operation.

Pre operative sensation, dexterity and grip power was determined for each patient and results were graded as per Sharma and Swamy grading system⁸ as good, fair and poor.(Table I)

Table I: Sharma and Swamy grading system

Dexterity Score	Grip Strength of the Hand(Affected Hand/Normal Hand) × 100	Sensibility Score	Appearance of the Hand(Ability to extend the fingers with the position of the Wrist)
Good ≥ 9	≥ 75	2	In slight Dorsiflexion
Fair 5 to 8	51 to 74	1	In Neutral Position
Poor ≤ 4	≤ 50	0	In Palmar Flexion

Sensation of the extremity was evaluated with the help of Semmes-Weinstein(SW) Monofilament test(Green Filament diameter 0.12 mm ,2.83 filament marking).⁸Autonomous zones of ulnar, median and radial nerves were checked by placing SW Monofilament perpendicular to the skin with enough pressure for one second. A score of 0 was given if the patient could not feel the SW monofilament at the three autonomous zones, a score of 1 was given if the patient perceived SW monofilament at the radial autonomous zone and a score of 2 when sensations were positive at all three autonomous zones.

Dexterity of the hand was determined with Sollerman Hand Function Test.¹⁵ Three tasks were used to assess fine functions of the hand. These tasks included picking coins from a purse, putting nuts on bolts and doing buttons of a shirt. The grading of these tasks were 0 meaning the tasks were not performed and 4 means that the tasks were completely performed within twenty seconds. The total score was

the sum of all 3 items(0 to 12). Jamar Dynamometer was used for determining grip power.¹⁶ Each hand was tested three times alternately and the mean value was calculated for each hand. The final result was calculated as a percentage of normal hand.

Surgical Technique

Under general anesthesia and tourniquet control, a lazy S-shaped incision was given starting from the medial epicondyle to the wrist level. The ulnar nerve was exposed first and was transposed anteriorly. Then, the flexor pronator mass was completely mobilized taking care not to expose the ulno-humeral joint. The muscles from the anterior surface of radius and ulna were elevated. Neurolysis of median and ulnar nerves were carried out at this stage if necessary. Care was taken not to injured anterior interosseous nerve and vessels. Passive stretch was applied to all fingers to stretch all the released muscles. Hemostasis was secured and wound was

closed. (Fig I) A full plaster of paris cast was applied in corrected position. All the patients were seen at 3rd week post operatively initially then monthly for three months and then at 6th months for two years.(Fig.II) All children were rehabilitated under the supervision of

a qualified physiotherapist and utilizing dynamic splints. In each visit the operated limb was assessed for sensation, dexterity and grip power and graded with Sharma and Swamy grading system as good, fair and poor.

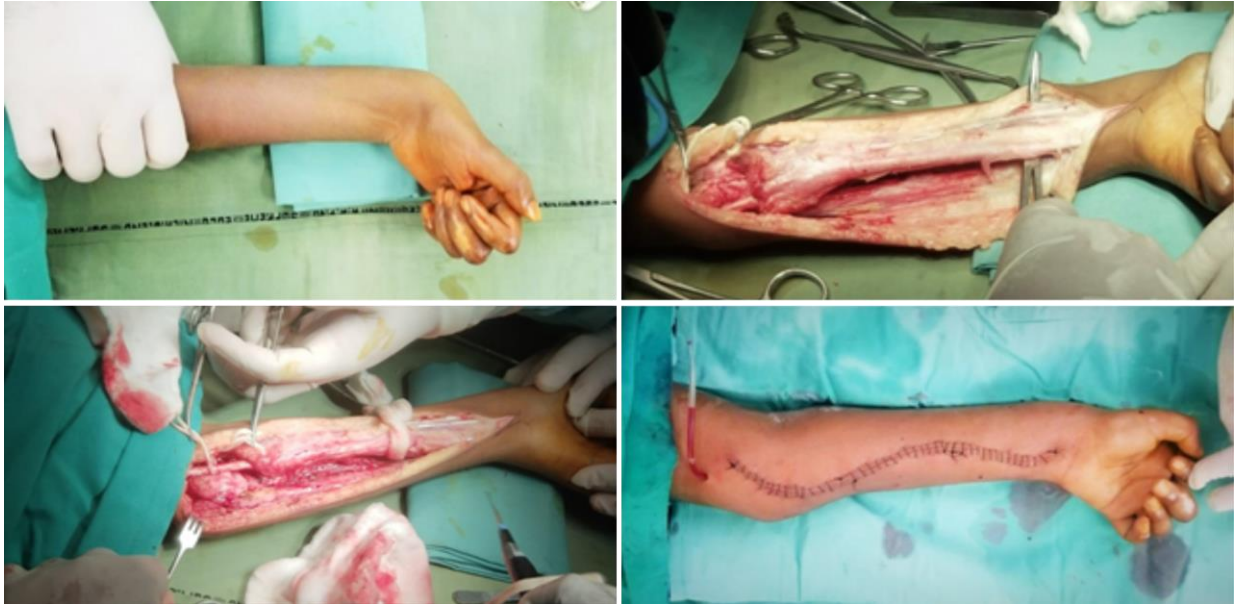

Fig I: Pre-op and Per-op pictures of Max-Page sliding operation.

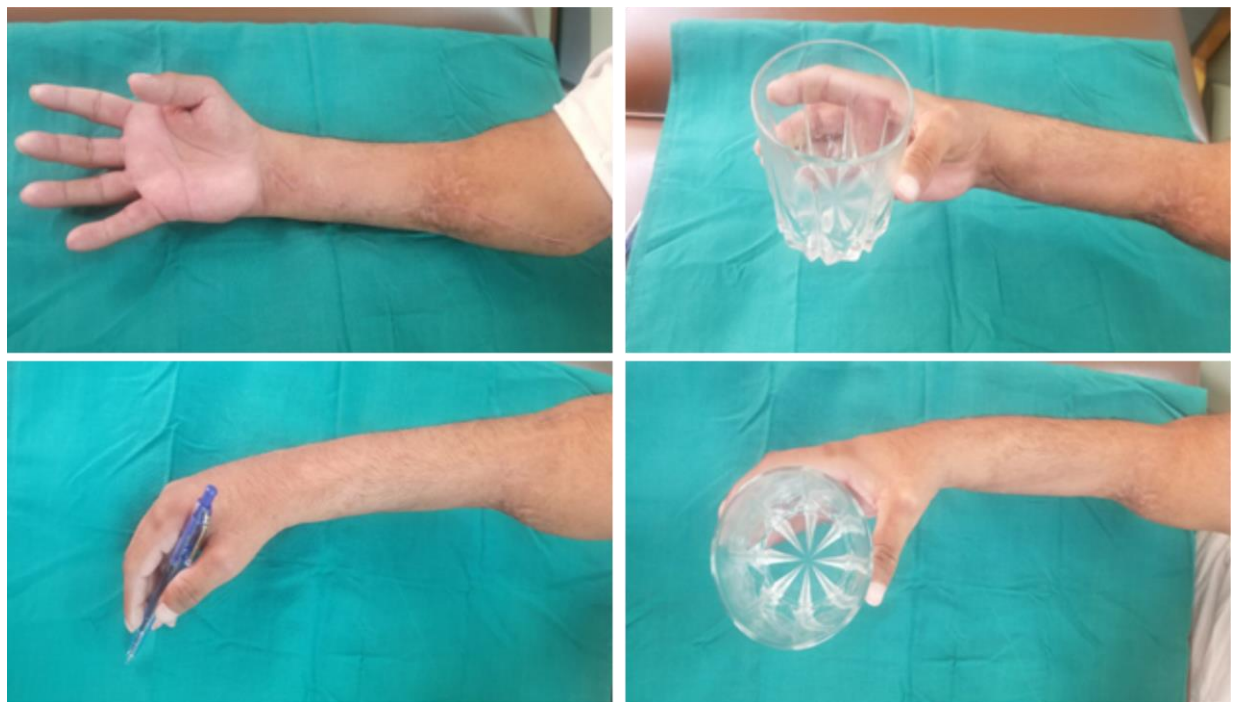


Fig II: Post-op functional outcome of Max-Page sliding operation

The data was analyzed with SPSS version 24. Important quantitative variables were represented as mean and standard deviation while qualitative

variables as frequency and percentages. T-test was applied to document statistically significant improvement ($P < 0.05$) between the pre operative

and post operative variables of sensation, dexterity and grip power (Sharma and Swamy grading system).The data was presented in table where necessary.

RESULTS

In our study 33 children with mean age 8.5 ± 4 years (range 5 to 12 years) were operated with Max Page muscle sliding operation. Male children were 20(60.6%) and female 13(39.4%). Right forearm VOIC was noted in 19(57.5%) while left side was involved in 14(42.4%) children. Majority(87.8%,n=29) of children had a history of fall,3(9%) had road traffic accidents and 1(3%) had a gunshot injury. VOIC following radius and ulna fracture was present in 19 (57.5%) patients, supracondylar fracture in 12 (36.5%) patients while 2(6%) patients had no fractures. Majority(72.7%,n=24) of our cases had a history of external bandages applied by bonesetters. Preoperative mean sensory score was 1.15 ± 0.38 and improved to 1.66 ± 0.22 ($P < 0.05$) post operatively. The grip strength improved from pre operative mean value of 10.3 ± 5 to post operative 80.3 ± 10 ($P < 0.05$).The dexterity score improved from pre operative 4 ± 1 to post operative 11.3 ± 7 ($P < 0.05$). Post operatively good functional outcome was noted in 25(75.5%) patients and fair in 8(24.2%) patients while no poor outcome was documented. Mean follow up was 13.09 ± 7.60 months. No per op or post complication was noted.

DISCUSSION

In our study the most common cause of VOIC was tight external bandages applied by bonesetters. This was also reported by another study.¹⁷ While radius and ulna fracture was the most common fractured bones in our study, supracondylar fracture was reported by others.^{14,18-20} Other rare causes of VOIC reported in literature are chemotherapy, extravasation of hypertonic dextrose and post radio-ulnar synostosis excision. ^{18,19,21}Max Page in 1923 stated that if the muscle bellies are spared, one can perform release of muscle insertions achieving excellent results.⁹ This technique was later popularized by Scaglietti²² and Gosset.²³ Since then this technique has produced remarkable results as compared to infarcted muscle excision and muscle lengthening.^{7,14}

In our study post operatively good functional outcome was noted in 25(75.5%) patients and fair in 8(24.2%) patients at 1 year follow up. Sharma and Swamy⁸ treated 19 patients of moderate VOIC with Max Page operation and reported good functional

outcome in 15(78.9%) patients, fair in 3(15.7%) and poor in 1(5.2%) patient. Post operative significant improvement was noted in dexterity score, sensibility, appearance and grip strength.($P < 0.05$) These authors concluded that Max Page operation is a simple and easy surgical technique for the treatment of moderate VOIC. However they suggested that complete muscle release and optimum post op physiotherapy was mandatory for achieving excellent results.

Eichler and colleagues¹⁹ reviewed the record of 38 patients of VOIC over a 10 year period at Mayo Clinic. Muscle slide was performed in 13 patients. Per operative full correction of the deformity was achieved in 9(69.2%) patients and partial in 4(30.7%).Adequate sensation and hand functions was noted in 5(38.4%) patients and without needing further surgical procedures while tendon transfers were required in 7(53.8%) patients and second muscle slide in 1(7.6%) patient. These authors were of the opinion that early release in established VOIC resulted in good functional outcome. Tsuge¹⁴ treated 14 patients with Max Page muscle sliding operation and reported good results in all and without any recurrence in the follow up. Dianming and Hong²⁴ treated 7 patients of VOIC with muscle slide and reported excellent outcome in 4(57.1%) and good in 2(28.5%) and fair in 1(14.2%) patient.

Our sample size was small and follow up period was short. We therefore recommend further comparative studies with enough sample size and longer follow up period to verify our results.

Conflict of Interest: None

Grants/Funding: None

CONCLUSION

Good functional outcomes was achieved in majority of moderate Volkmann's ischemic contractures operated with Max Page muscle sliding operation. We therefore recommend Max Page muscle sliding operation as the operation of first choice to treat moderate VOIC of the forearm. However, selection of the patients must be proper, release must be adequate and post operative rehabilitation protocol must be optimum and focused.

REFERENCES

1. Volkmann R. Die ischaemischen muskellahmungen und kontracturen. Zentralbl Chir.1881;8:801-803.
2. Thomas JJ. Nerve involvement in the ischemic paralysis and contracture of Volkmann. Ann Surg.1975; 57 A:925-929.

3. Brooks B. Pathological changes in muscle as a result of disturbances of circulation: an experimental study of Volkmann's ischaemic paralysis. *Arch Surg.*1992;5:188-216.
4. Leriche R. Surgery of the sympathetic system: Indicators and results. *Ann Surg.*1928; 88:449
5. Griffiths DV. Volkmann's ischaemic contracture. *Br J Surg.*1940;28:239-260.
6. Yamaguchi S, Viegas SF. Causes of upper extremity compartment syndrome. *Hand Clin.*1998; 14:365-370.
7. Seddon HJ. Volkmann's contracture: Treatment by excision of the infarct. *J Bone Joint Surg.*1956; 32B:152-174.
8. Sharma P, Swamy KS. Results of the Max Page muscle sliding operation for the treatment of Volkmann's ischemic contracture of the forearm. *J Orthop Traumatol.*2012;13(4):189-196.
9. Page C. An operation for the relief of flexion-contracture in the forearm. *J Bone Joint Surg.*1923;5:233-4.
10. Stevanovic M, Sharpe F. Management of Established Volkmann's Contracture of the Forearm in Children. *Hand Clin.*2006; 22 :99-111.
11. Stevanovic M, Sharpe F. Late Management of Compartment Syndrome. In: Abzug J, Kozin S, Zlotolow D, editors. *The Pediatric Upper Extremity.* New York: Springer;2014.p.1-29.
12. Nisbet NW. Volkmann's Ischaemic contracture benefited by muscle slide operation: Report of a Case. *J Bone Joint Surg Br.* 1952;34(2):245-7.
13. Saaq M. Clinical and Demographic Profile of Volkmann's Ischemic Contractures Presenting at National Institute of Rehabilitation Medicine, Islamabad, Pakistan. *World J Plast Surg.* 2020; 9(2): 166-173.
14. Tsuge K. Management of established Volkmann's contracture. *J Bone Joint Surg.*1975;57A:925-929.
15. Sollerman C, Ejeskar A. Sollerman hand function test. A standardised method and its use in tetraplegic patients. *Scand J Plast Reconstr Surg Hand Surg.*1995;29(2):167-76.
16. Shah FA, Alam W, Durrani Z, Askar Z, Khan MA, Hayat S. Outcome of closed reduction and plaster cast immobilization of fracture distal radius in adults. *Pak J Surg.* 2010; 26(4):315-319.
17. Sundararaj GD, Mani K. Pattern of contracture and recovery following ischaemia of the upper limb. *J Hand Surg Br.*1985;10:155-161.
18. Reigstad A, Hellum C. Volkmann's ischaemic contracture of the forearm. *Injury.*1980;12:148-150.
19. Eichler GR, Lipscomb PR. The changing treatment of Volkmann's ischemic contractures from 1955 to 1965 at the Mayo clinic. *Clin Orthop.*1967;50:215-21.
20. Ultee J, Hovius SER. Functional results after treatment of Volkmann's ischemic contracture: a long-term follow up study. *Clin Orthop.*2005; 431:42-49.
21. Chuang DC, Carver N, Wei FC. A new strategy to prevent the sequelae of severe Volkmann's ischaemia. *Plast Reconstr Surg.*1996; 98:1023-1031.
22. Scaglietti O. Chirurgische Behandlung der Volkmann'schen Paralyse. *Verh Dtsch Orthop Ges.* 1957;45:219-223.
23. Gosset J, La de sinserion chirurgicale des muscles de la loge ante rieure de l'avantbras dans le traitement des contractures et re actions ische miques. *Ann Chir.*1956; 32:509-515.
24. Dianming J, Hong A, Liying M. Sliding of flexor muscles for treatment of Volkmann's contracture of the forearm. *Chin J Hand Surg.*1998;25-32.