

Reamer-Irrigation-Aspiration (RIA) system: The Game Changer.

Faaz Ali Shah¹, Mian Amjad Ali²

¹Assistant Professor Orthopaedics & Traumatology Lady Reading Hospital Peshawar

²Professor Orthopaedics & Traumatology Lady Reading Hospital Peshawar

Corresponding author:

Mian Amjad Ali

E-mail: drmianamjadali@gmail.com

Intramedullary nailing of long bone fractures have been associated with fat embolism and thermal necrosis due to reaming.^{1,2} An attempt to reduce the incidence of these complications Reamer-Irrigation-Aspiration(RIA) system was developed (Synthes, Paoli, PA, USA). This innovative system provides simultaneous continuous irrigation and suction while reaming long bones. The marrow contents, bone fragments and irrigation fluid is passed through a filter first and then into a suction bag. The second generation RIA system was launched in 2019 (Fig. 1). It has new design for easy handling, small reamer head size of 10 mm (first generation RIA system has 12 mm reamer head size) and has larger holes for improved irrigation and suction. The design and characteristics of this reamer are different from standard reamer and detailed guidelines of RIA technique and usage has already been established.³ The purpose of this editorial is to update the Orthopaedic community of Pakistan about the expanded indications, safety and efficacy of RIA system.

The indications of RIA have been expanded recently. It has been used for treating post operative osteomyelitis,⁴ non unions of long bone⁵⁻⁹ and for obtaining mesenchymal stem cells.¹⁰ Zalavras⁴ treated 8 tibial osteomyelitis and 3 femur osteomyelitis with debridement of the medullary canals utilizing RIA system and reported no infection at six months follow up.

This article may be cited as:

Shah FA, Ali MA. Reamer-Irrigation-Aspiration (RIA) system: The Game Changer. J Pak Orthop Assoc 2021;33(3):

With RIA system 40 to 90 ml of graft can be obtained in comparison to 20 to 40 ml of cancellous bone graft from iliac crest.⁶⁻⁸ The graft obtained with RIA system has comparable Osteoinductive properties to that of iliac crest bone graft¹¹ and union rates of 90% have been reported with this bone graft.⁵⁻⁹ Post operative pain is less in patients in whom graft have been obtained with RIA system than obtained from iliac crest graft.⁷ The United States Food and Drug Administration(FDA) has approved RIA system for harvesting autogenous bone graft in March 2005.¹² Although RIA system is costly but for surgeries requiring larger volume of bone graft it has been found cost effective.¹³ RIA bone graft has been used successfully in spinal fusion and opening wedge high tibial osteotomy.^{14,15} Vincenti *et al*¹⁶ treated 17 patients of infected non union of tibia with Gentamicin-Coated nail and RIA system and noted healing in all patients in 7.8 months.

Mesenchymal stem cells (MSCs) are obtained from bony fragments and filtrate of RIA. The RIA

filtrate has higher volume of concentrated MSCs¹⁷ in comparison to aspirates from iliac crest which has only 0.001 to 0.01% cells.^{18,19} MSCs are multipotential bone marrow stromal cells with chondrogenic characteristics.¹⁰ The MSCs of RIA in combination with dexamethasone had been successful in treating non union in 12 out of 13 bone specimens in vitro.²⁰ Schmidmaier *et al*¹¹ revealed that RIA has more potent Osteoinductive properties than conventional bone graft obtained from iliac crest and this is due to the larger quantity of Bone Morphogenetic Protein(BMP-2), Transforming Growth Factor (TGD- β 1), Fibroblast Growth Factor (FGFa), Insulin Growth Factor (IGF-1) and Platelet Derived Growth Factor (PDGF bb) present in RIA. Tossi *et al*²¹ compared MSCs obtained from RIA, iliac crest marrow and adipose tissue and found that MSCs derived from RIA had greater and faster chondrogenic and osteogenic differentiation capacity than the other two. Tossi *et al* recommend the use of MSCs of RIA for treating Orthopaedic disorders.

RIA system is very useful for fixation of pathological or impending femur fractures in patients with metastasis with the added advantage of lowering the risk of distal metastasis, decreasing the tumour burden and systemic dissemination and obtaining adequate samples for histological grading.^{22,23} RIA system can be used for removal of cement fragments after removal of antibiotic coated nail or cemented hip arthroplasty especially if removal is difficult with conventional standard instruments.³ Several authors have used the membrane induced technique of Masquelet with autograft obtained from RIA. Stafford²⁴ treated 27 bone defects with 1 to 25 cm gaps with autograft of RIA and Masquelet technique and achieved union in 24(89%) patients.

The RIA system is a safe technique with relatively few complications. We found only 3 complications in 87 patients in 5 studies. These were anterior femoral cortex perforation, fracture neck of femur and hypertrophic scar formation.⁵⁻⁹ All these complications were successfully treated with conventional techniques. Eccentric reaming or over reaming of the femur particularly in osteoporotic patients and in those with non alignment of medullary canal can cause perforation.^{7,24} Complications of the RIA system can be avoided with proper pre operative assessment of the diameter of cortex, optimum per operative entry point of the reamer, central placement of the guide wire, reaming 2 mm less than the isthmus diameter and frequent use of fluoroscopy during reaming.²⁵ Other potential complications are dislodgment of reamer head from the drive shaft, breakage of tip of the drive shaft and blockage of tube assembly by debris due to prolonged reaming and irrigation.^{23,24-27} RIA is contraindicated in diaphyseal infection with narrow medullary cavity (< 10 mm diameter).²⁸ Marchand²⁹ was of the opinion that patients operated for obtaining bone graft with RIA system were more likely to required blood transfusion than those operated for conventional iliac crest graft.

The RIA system is a versatile device with minimal complications. It is user friendly and has a short learning curve. It should gain popularity among the Orthopaedic surgeons of Pakistan. The issue of cost can be resolved if local version of RIA system is manufactured by our biomedical engineers. Routine clinical use of RIA system will further validate its indications and outcome in Pakistani population.

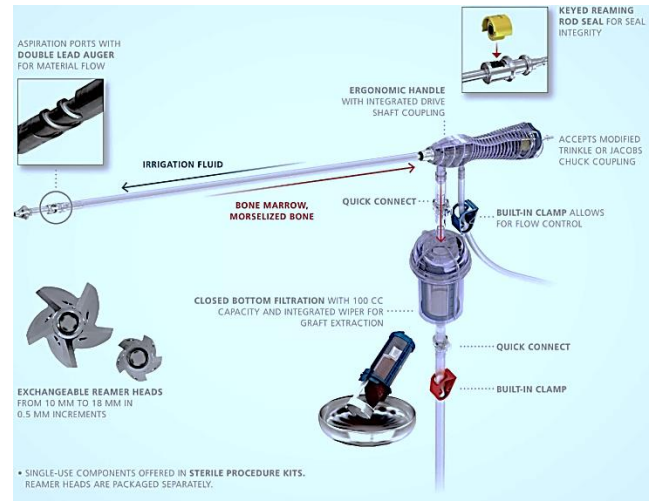


Fig. 1: The Reamer-Irrigation-Aspiration (RIA) system (The DePuy Synthes RIA 2)

Conflict of Interest: None

Grants/Funding: None

REFERENCES

1. Glover P, Worthley LI. Fat embolism. *Crit Care Resusc* 1999;1(3):276-284.
2. Giannoudis PV, Snowden S, Matthews SJ, Smye SW, Smith RM. Temperature rise during reamed tibial nailing. *Clin Orthop Relat Res* 2002; 395:255-261.
3. Giannoudis PV, Tzioupis C, Green J. Surgical techniques: How I do it? The reamer/irrigator/aspirator (RIA) system. *Injury* 2009; 40(11):1231-1236.
4. Zalavras CG, Singh A, Patzakis MJ. Novel technique for medullary canal debridement in tibia and femur osteomyelitis. *Clin Orthop Relat Res* 2007; 461:31-34.
5. Kobbe P, Tarkin IS, Pape HC. Use of the 'reamer irrigator aspirator' system for non-infected tibial non-union after failed iliac crest grafting. *Injury* 2008; 39(7):796-800.
6. Newman JT, Stahel PF, Smith WR, Resende GV, Hak DJ, Morgan SJ. A new minimally invasive technique for large volume bone graft harvest for treatment of fracture nonunions. *Orthopedics* 2008; 31(3):257-261.
7. Belthur MV, Conway JD, Jindal G, Ranade A, Herzenberg JE. Bone graft harvest using a new intramedullary system. *Clin Orthop Relat Res* 2008; 466(12):2973-2980.
8. McCall TA, Brokaw DS, Jelen BA, Scheid DK, Scharfenberger AV, Maar DC, *et al.* Treatment of large segmental bone defects with reamer-

- irrigator-aspirator bone graft: technique and case series. *Orthop Clin North Am* 2010; 41(1):63-73.
9. Stafford PR, Norris B. Reamer-irrigator-aspirator as a bone graft harvester. *Tech Foot Ankle Surg* 2007; 6:100-107.
 10. Porter RM, Liu F, Pilapil C, Betz OB, Vrahas MS, Harris MB, et al Osteogenic potential of reamer irrigator aspirator (RIA) aspirate collected from patients undergoing hip arthroplasty. *J Orthop Res* 2009; 27(1):42-49.
 11. Schmidmaier G, Herrmann S, Green J, Weber T, Scharfenberger A, Hass NP, et al Quantitative assessment of growth factors in reaming aspirate, iliac crest, and platelet preparation. *Bone* 2006; 39(5):1156-1163.
 12. Hartsock LA, Barfield WR, Kokko KP, Liles LL, Wind T, Green J, et al. Randomized prospective clinical trial comparing reamer irrigator aspirator (RIA) to standard reaming (SR) in both minimally injured and multiply injured patients with closed femoral shaft fractures treated with reamed intramedullary nailing (IMN). *Injury* 2010;41:94-98.
 13. Dawson J, Kiner D, Ii WG, Swafford R, Nowotarski PJ. The Reamer Irrigator Aspirator as a device for harvesting bone graft compared with iliac crest bone graft: union rates and complications. *J Orthop Trauma* 2014;28:584-590.
 14. Nichols TA, Sagi HC, Weber TG, Guiot BH. An alternative source of autograft bone for spinal fusion: the femur: technical case report. *Neurosurgery* 2008;62:66.
 15. Seagrave RA, Sojka J, Goodyear A, Munns SW. Utilizing reamer irrigator aspirator (RIA) autograft for opening wedge high tibial osteotomy: A new surgical technique and report of three cases. *Int J Surg Case Rep* 2014;5:37-42.
 16. Vincenti G, Bizzoca D, Cotugno D, Carrozzo M, Riefoli F, Rifino F, et al. The use of gentamicin-coated titanium nail, combined with RIA system in the management of non-union of open tibial fractures: A single centre prospective study. *Injury* 2020;51(3):86-91.
 17. Higgins TF, Casey V, Bachus K. Cortical heat generation using an irrigating/aspirating single-pass reaming vs conventional stepwise reaming. *J Orthop Trauma* 2007; 21(3):192-197.
 18. Castro-Malaspina H, Gay RE, Resnick G, Kapoor N, Meyers P, Chiarieri D, et al. Characterization of human bone marrow fibroblast colony-forming cells (CFU-F) and their progeny. *Blood* 1980; 56:289-301
 19. Jones EA, Kinsey SE, English A, Jones RA, Straszynski L, Meredith DM, et al. Isolation and characterization of bone marrow multipotential mesenchymal progenitor cells. *Arthritis Rheum* 2002; 46(12):3349-3360.
 20. Miller MA, Ivkovic A, Porter R, Harris MB, Estok DM, Smith RM, et al. Autologous bone grafting on steroids: preliminary clinical results. A novel treatment for nonunions and segmental bone defects. *Int Orthop* 2010;121-129.
 22. Toosi S, H Naderi-Meshkin H, Kalalinia F, Peivandi MT, Khani HH, Bahrami AR et al. Comparative characteristics of mesenchymal stem cells derived from reamer-irrigator-aspirator, iliac crest bone marrow, and adipose tissue. *Cell Mol Biol (Noisy-le-grand)* 2016;62(10):68-74.
 23. Kanakaris NK, Morell D, Gudipati S, Britten S, Giannoudis PV. Reaming Irrigator Aspirator system: early experience of its multipurpose use. *Injury* 2011;42:28-34.
 24. Stafford PR, Norris BL. Reamer-Irrigator-Aspirator bone graft and bi Masquelet technique for segmental bone defect non unions: A review of 25 cases. *Injury* 2010;41(Suppl 2):72-77.
 25. Dehghan N, Schemitsch EH, Extended applications of the reamer-irrigator-aspirator (RIA) system. *Injury* 2017;234-249.
 26. Jakma TSC, Roling MA, Punt B, Reynders-Frederix P. More adverse events than expected in the outcome after use of the reamer-irrigator-aspirator. *Eur J Trauma Emerg Surg* 2013;40:337-341.
 27. Cipriano CA, Arvanitis LD, Virkus WW. Use of the reamer-irrigator-aspirator may reduce tumor dissemination during intramedullary fixation of malignancies. *Orthopedics* 2012;35:48-52.
 28. Bellapianta J, Gerdeman A, Sharan A, Lozman J. Use of the reamer irrigator aspirator for the treatment of a 20-year recurrent osteomyelitis of a healed femur fracture. *J Orthop Trauma* 2007;21:343-346.
 29. Marchand LS, Rothberg DL, Kubiak EN, et al. Is this autograft worth it? The blood loss and transfusion rates associated with reamer irrigator aspirator bone graft harvest. *J Orthop Trauma* 2017;31(4):205-209.