

Percutaneous Pinning in Gartland Type-II and III Supracondylar Fractures

Anwar ul Haq, Syed Muhammed Ali, Imtiaz Ahmed Tago, Siraj Ahmed Butt

ABSTRACT

Objective: To explore the safety and effectiveness of the percutaneous pinning technique in the management of Gartland type-II and III supracondylar humerus fractures.

Methods: This study was carried out during January 2012 to March 2013. 30 children with age range 5-12 years with supracondylar fracture (Gartland type II & III) were included while others were excluded. Closed reduction and percutaneous pinning were performed after taking informed consent. Outcomes were recorded according to Flynn's criteria, that is loss of elbow motion & carrying angle.

Results: There were 21 (70%) males and 9 (30%) females in the current study. 18 (60%) patients were having right side affected while 12 (40%) had left side. The mean age of study subjects was 8.07+ 2.033 years. The distribution of Gartland Type-III and II fractures was 19 (63.33%) and 11 (36.66%) respectively. Hospital stay time was 6-28 hours with most of the patients discharged on the same postoperative day. Removal of Posterior slab and pin was carried out after 2-4 weeks and 3-4 weeks respectively. Flynn's criteria showed 20 (66.66%), 8 (26.66%), 2 (6.66%) excellent, good and fair results respectively. Similarly Flynn's criteria for assessing loss of range of motion, 17 (56.66%), 9 (30%), 4 (13.33%) patients had excellent, good and fair outcomes respectively. No neurovascular injury was observed during operation as well as postoperatively.

Conclusion: Percutaneous pinning is an effective and safe technique in Gartland Type-II & III Supracondylar fractures in children.

Key words: Gartland fractures, Flynn's criteria, percutaneous pinning.

INTRODUCTION

Supracondylar fracture is the most common fracture of humerus as well as among the other fractures involving elbow joint, accounting for 60% of the fractures the elbow joint [1,2,3,4]. The occurrence in children is mostly observed in 1st decade of child age [5,6,7]. Gartland's classification further divides the extension type fractures into 3 types based on the degree of displacement of distal portion. These are type-I (undisplaced), type-II (Partially displaced) and type-III (completely displaced) there is no connection between fragments [8]. Conservative as well the operative management is a difficult task for such displaced supracondylar fracture [8]. There are different treatment options proposed including closed

reduction, Dunlop's skin traction, plaster cast immobilization, skeletal traction, closed reduction Kirschner wire fixation and percutaneous pinning [9,10,11]. These fractures if treated by potter / doctor have serious complications such as myositis ossificans, Volkmann's ischemic contracture, arterial injury, nerve injury, and cubitus varus deformity [11,12]. These hazards are less likely associated percutaneous pinning [13]. Results are achieved to an excellent level with percutaneous pinning for both Gartland type-II & III supracondylar fractures by Swenson technique. The prognosis of the procedure is assessed by Flynn's criteria. The procedure is very simple with excellent results in comparison to other pin configurations [14,15,16,17,18].

*Department of Orthopaedic Surgery & Traumatology,
Liaquat University of Medical & Health Sciences
Jamshoro*

*Correspondence: Syed Muhammed Ali
Email: muhammad.ali@lumhs.edu.pk*

METHODS

Duration of study was one year and three months (January 2012- March 2013). Young patients were selected by inclusion criteria through non-probability, convenience sampling. 30 children could be registered

during whole study period having Type-II Gartland or Type-III supracondylar humeral fracture. Informed and written consent from parents was obtained prior to surgery. The Initial management was with Back Slab subsequently followed by the surgery.

PROCEDURE

Under general anaesthesia and aseptic measures longitudinal traction was applied with elbow in extension and forearm in supination with an assistant applying counter traction to disimpact the fracture (Fig:1). All procedure was assessed under image intensifier. Medial or lateral displacement was corrected by applying a varus or valgus force then angulation was corrected by flexing the elbow with continued traction. Position of the arm was in maximum external rotation on the fluoroscopy platform in case of posteromedial displacement while in the posterolateral displacement the arm was in maximum internal rotation.

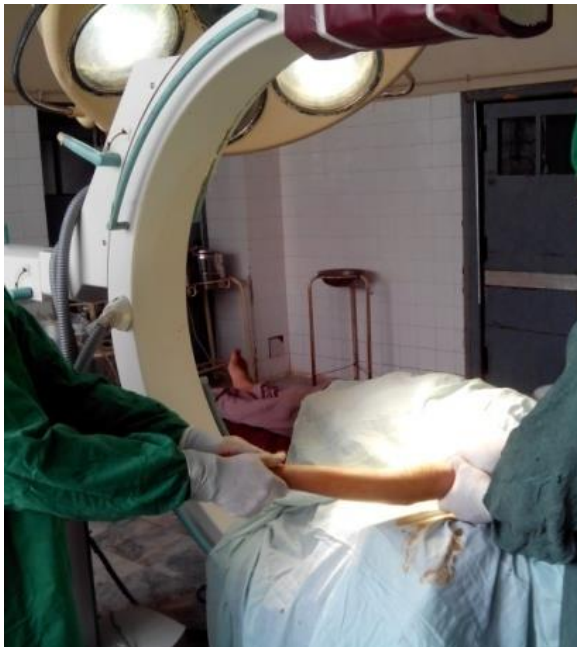

Fig 1: Reduction by traction in extension under general anaesthesia.

When fracture reduction was fluoroscopically acceptable, reduced fracture was stabilized with the Kirschner wires (1.5–2.0 mm) from the lateral epicondyle through a stab wound. Direction of pins was upward and medially at an angle of 35–40° to the sagittal plane of the humerus. The pin thus passed through the distal fragment and medullary cavity of the

proximal fragment to engage the cortex of the proximal fragment about 3 cm above the fracture line. Before the insertion of medial pin the elbow was extended and assessed the Bowman's angle and anterior humeral line, if acceptable then medial pin was inserted through the center of the medial epicondyle in a similar manner. The pins should cross each other 1.5–2 cm above the fracture line. In either case, posterolateral or posteromedial displacement, the first wire was inserted from the lateral side. In certain cases another wire was also inserted through the lateral epicondyle in divergent or parallel configuration to increase the stability. Radial pulse was intermittently checked. The ulnar nerve in the ulnar groove was easily avoided. On swelled arm, medial wire was passed by direct vision after exploring the medial epicondyle anteriorly by a small incision. Radial pulse reassessed and final reduction and pin placement was checked by both A-P and lateral view image under image intensifier (Fig: 2). The pins were cut off and clinical assessment was done by checking the amount of flexion possible and by measuring the carrying angle of the forearm. Aseptic dressing and above elbow back slab was applied.

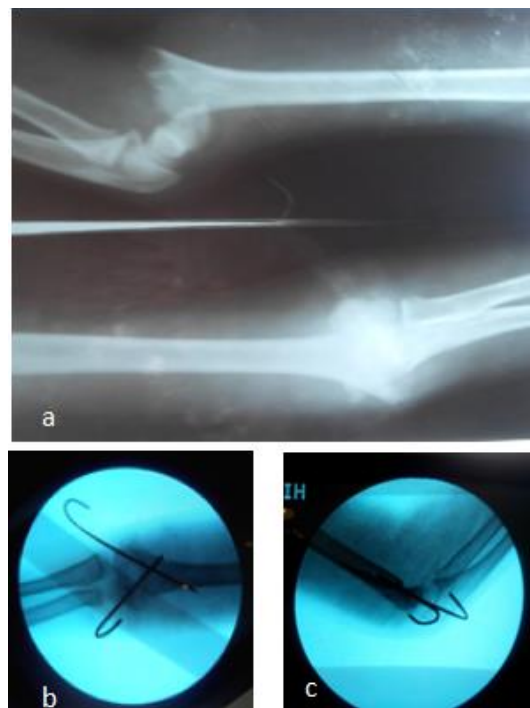

Fig. 2: a) Gartland grade-III supracondylar fracture A-P and lateral view. b) Close reduction and cross K-wire fixation (A-P view). c) Close reduction and cross K-wire fixation (lateral view).

Neurovascular status of the patient's limb was assessed after recovery from anaesthesia. Postoperative radiographs AP and Lateral views were done. Patient was discharged on same day or on 1st postoperative day.

Follow-up of the patients was done at weekly intervals. On radiological evidence of callus formation and clinical assessment of fracture union Kirschner wires were removed and active exercises were started. Thereafter follow-up evaluation was done at weekly intervals till the maximum rehabilitation (range of movement) achieved, then monthly intervals for 6 months. On follow-up, patients were assessed clinically and radiologically and results were evaluated on the basis of Flynn's criteria.

Children of age range 5- 12 years with either Type-II or Type-III Gartland fractures were included & children with local injury abdominal trauma, head injury and other co morbidity were excluded.

SPSS Version 22 was used for data analysis, mean and SD was determined for numerical variables like age and time of pin removal while percentage (%) for the qualitative variable e.g. Gender, fracture type, and

outcome in grade Excellent, Good and Poor. No statistical test could be used, as the nature of data was descriptive.

RESULTS

19 patients had Gartland type-III fracture and 11 patients presented with Gartland type-II. 21 subjects were males and 9 were females. Mean age of the study subjects was 8.07+2.033 and ranged 5 -12 years. Right side was affected in 18 children while 12 had fractures on left side. 19 subjects had posteromedial and 11-presented posteriolateral displacement. Operative time duration took 20- 45 minutes. Flynn's criteria showed 20 (66.66%) patients had excellent outcome however 8 (26.66%) and 2 (6.66%) had good and fair respectively. Results about loss of movement range were 17 (56.66%), 9(30%), 4 (13.33%) had excellent, good and fair respectively. Radiological union took 3 to 6 weeks with 3.9 weeks as an average. Pins removal duration was within 3 to 4 weeks.

Table-1: Age and Sex Distribution of Study Population: (N=30)

Sex	No. of patients	Percentage	Minimum age	Maximum age	Mean and s.d
Total	30	100%	5	12	8.07+2.033
Male	21	70%	5	12	7.42+3.5
Female	9	30%	8	12	9.55+1.5

Graph 1:

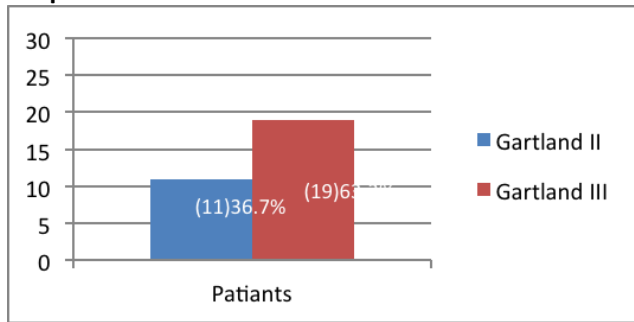


Table-3: Results According To Flynn's Criteria.(N=30)

Grading	Loss of carrying angle (Degrees)	Loss of movement (Degrees)
Excellent	20 (66.66%) (0-5 ⁰)	17 (56.66%) (0-5 ⁰)
Good	08 (26.66%) (5-10 ⁰)	09 (30%) (5-10 ⁰)
Fair	02 (6.66%) (10-15 ⁰)	04 (13.33%) (10-15 ⁰)
Poor	0 (0%) (>15 ⁰)	0 (0%) (>15 ⁰)

Table-2: Flynn's Criteria

Result	Loss of Carrying Angle (Degrees)	Loss of Movement (Degrees)
Excellent	0—5 ⁰	0—5 ⁰
Good	5—10 ⁰	5—10 ⁰
Fair	10—15 ⁰	10—15 ⁰
Poor	>15 ⁰	>15 ⁰

DISCUSSION

Managing a displaced supracondylar fracture is a hard task in children and aims to achieve normal looking elbow having good range of movements with well-reduced and stabilized fractured bone.

Among the different ways of non-surgical treatments are closed manipulation to reduce the fracture and stabilization with plater cast and different

types of tractions including skin and skeletal traction while operative management includes close manipulation, reduction and stabilization with percutaneous k-wires and open reduction and internal fixation with k-wires for the displaced supracondylar fracture of humerus in children [2,8,9].

Closed reduction and above elbow plaster cast is more suitable for Gartland type-I fractures in comparison to displaced supracondylar fractures. Skin and skeletal traction procedure has much compliance issue for children and parents. It also needs the longer hospital as well some reliability problems in children. Open reduction and internal fixation by k-wires is associated with Infection and joint stiffness. These can be preferred in patients with late presentation where closed reduction is not possible similarly if the image intensifier availability is the issue. So closed reduction and percutaneous pinning remains the best option for managing Gartland type-II and III displaced supracondylar fractures [3]. This procedure has many advantages including reduced hospital stay, safe limb splinting without any risk of fracture reduction, chances of infection are very low, achievement of early and maximum range of motion along with reduced risk of complications [16].

Iqbal J (2011) and Shaikh AM (2014) concluded excellent outcomes with crossed pin fixation [15,19,20], however other studies suggested that lateral condylar pin fixation in parallel or crossed configuration may reduce the chances of ulnar nerve injury [1,18,21]. Many searches were of open in that medial and lateral crossed pin fixation is the most stable configurations biomechanically [21,22,23,24,25]. Small sample size remained a short fall of our study needs someone else to cover.

CONCLUSION

Our present study concluded that best preferred treatment modality in displaced supracondylar fractures of humerus is a closed reduction and crossed percutaneous pinning of medial and lateral condyles. It is a safe, cost effective, having limited operative time, less complications and provides greater skeletal stability with excellent functional and cosmetic results when surgical technique followed strictly.

REFERENCES

1. Mostafavi HR. Spero C. Crossed pin fixation of displaced supracondylar humerus fractures in

- children. *Clin Orthop Relat Res.* 2000 Aug;(376):56–61.
2. Ambrosia D. Robert RD. Supracondylar fractures of humerus – prevention of cubitus varus. *J Bone Joint Surg Am.* 1972 Jan;(54):60–66.
3. Lins RE. Simovitch RW. Waters PM. Pediatric Elbow Trauma. *Orthop Clin North Am* 1999 Jan;30(1):119-132.
4. Beatty JH, Kasser JR, Skaggs DL, Flynn JM, Waters PM. Rockwood and Wilkins' fractures in children. 7th ed. Philadelphia: Lippincott Williams & Wilkins; 2007
5. Eliason EL. Dressing for supracondylar fracture of humerus. *JAMA* 1924 Jun; 82(24): 1934-1935.
6. Wilson PD. Fractures and dislocation in the region of elbow. *Surg Gynecol obstet* 1933; 56: 335-59.
7. Abraham E, powers T-Vitt. Excremental hyper extension of supracondylar fracture in monkeys. *Clin Orthop* 1982; 171: 309-18.
8. Gartland JJ. Management of supracondylar fractures in children. *Surg Gynecol Obstet.* 1959 Aug;109(2):145–154.
9. Dunlop J. Transcondylar fracture of the humerus in children. *J Bone Joint Surg. Am.* 1939 Jan;21(1):59–73.
10. Dodge HS. Displaced supracondylar fractures of the humerus in children – treatment by Dunlop's traction. *J Bone Joint Surg. Am.* 1972 Oct;54(7):1408–1418.
11. Mazda K. Boggione C. Fitoussi F. Penneçot GF. Systematic pinning of displaced extension-type of supracondylar fractures of the humerus in children. A prospective study of 116 consecutive patients. *J Bone Joint Surg. Br.* 2001 Aug;83(6):888–893.
12. Davis RT. Gorczyca JT. Pugh K. Supracondylar humerus fractures in children. Comparison of operative treatment methods. *Clin Orthop Relat Res.* 2000 Jul;376:49–55.
13. Piron AM. Gronam HK. Kraj Bich JI. Management of displaced extension type of supracondylar fracture of humerus in children. *J Bone Joint Surg.* 1988 Jun;70(5): 641-50.
14. Royce RO. Dutkowsky JP. Kasser JR. Rand FR. Neurologic complications after K-wire fixation of supracondylar humerus fractures in children. *J Pediatr Orthop.* 1991 Mar-Apr;11(2):191–194.
15. Swenson AL. The treatment of supracondylar fractures of the humerus by Kirschner-wire

- transfixion. *J Bone Joint Surg. Am.* 1948 Oct;30(4):993–997.
16. Flynn JC, Matthews JG, Benoit RL. Blind pinning of displaced supracondylar fracture of the humerus in children. Sixteen years' experience with long-term follow-up. *J Bone Joint Surg. Am.* 1974;56:263–272.
 17. Joes KG. Percutaneous pin fixation of fractures of the lower end of the humerus. *Clin Orthop Relate Res* 1967 Jan-Feb;50:53-69.
 18. Wang X. Feng C. Wan S. Bian Z. Zhang J. Song M. et al. Biomechanical analysis of pinning configurations for a supracondylar humerus fracture with coronal medial obliquity. *J Pediatr Orthop B.* 2012 Nov;21(6):495–498. doi: 10.1097/BPB.0b013e328355d01f.
 19. Iqbal J. Supracondylar fracture of humerus in children. An experience of closed reduction and percutaneous pinning. *Ann King Edward Med Coll* 2011 Dec;7(4): 278-80.
 20. Shaikh AM. Tunio MZ, Shah SNH, Qazi MA. Gartland Type III Supracondylar fracture of humerus with closed reduction and percutaneous fixation with K-wires in children. *J Pak Ortho Assoc.* 2014 March; 26(1): 25-28.
 21. Brauer CA. Lee BM. Bae DS. Waters PM. Kocher MS. A systematic review of medial and lateral entry pinning versus lateral entry pinning for supracondylar fractures of the humerus. *J Pediatr Orthop.* 2007 Mar;27(2):181–186. doi: 10.1097/bpo.0b013e3180316cf1.
 22. Zoints LE. McKellop HA. Hathaway R. Torsional strength of pin configurations used to fix supracondylar fracture of the humerus in children. *J Bone Joint Surg. Am* 1994 Feb;76(2):253–256.
 23. Herzenberg Jt, Koreska J, Carroll NC, Rang M. Biochemical testing of fixation technique for pediatric supracondylar elbow fractures. *Orthop Trans.* 1988;12:678–679.
 24. Li YA. Lee PC. Chia WT. Lin HJ, Chiu FY. Chen TH. Et al. Prospective analysis of a new minimally invasive technique for paediatric Gartland type III supracondylar fracture of the humerus. *Injury.* 2009 Dec;40(12):1302–1307. doi: 10.1016/j.injury.2009.03.007.
 25. Yen YM. Kocher MS. Lateral entry compared with medial and lateral entry pin fixation for completely displaced supracondylar humeral fractures in children: surgical technique. *J Bone Joint Surg. Am.* 2008 Mar;90 suppl 2 pt 1:20–30.
-