

# Intramedullary Fixation in Pediatric Femoral Fractures at Tertiary Care Hospital

Alamzeb Khan Swati

## ABSTRACT

**Objective:** To determine outcome of intramedullary fixation with rush rods in pediatric femoral fractures at tertiary care hospitals.

**Methods:** This case series study was conducted from June 2009 to December 2010. Study included 40 patients of pediatric age fresh femoral fractures admitted in department either OPD or emergency. Preoperative diagnosis was made on antero posterior and lateral views of plain x-rays. Intramedullary fixation of all femoral fractures was done with rush pins under image control. All postoperative patients were followed regularly on OPD basis and outcome of intramedullary fixation was determined on 6<sup>th</sup> postoperative month.

**Results:** There were 40 patients who underwent fixation of 41 femur fractures (one patient had bilateral fracture). Age ranges from 6 to 12 years with a mean of 8.25 years. There were 24 males and 16 females. Minor complications were observed in 19 patients and major complications were observed in 6 patients. Outcome was graded as excellent in 23 patients (57.15%), successful in 12 patients (28.57%) and poor in 6 patients (14.28%).

**Conclusion:** Intramedullary fixation of pediatric femoral fractures with rush rods showed good results allowing early ambulation.

**Keywords:** Pediatric femoral fractures, Intramedullary fixation, Spica, Plating.

## INTRODUCTION

Femur shaft fractures are among the most common paediatric injuries managed by Orthopedic Surgeons [1]. Shaft fractures are more common as compared to other sites in the femur. Femoral shaft fractures in children are directly linked with morbidity [2]. Management of femur shaft fractures depends upon number of variables including mode of injury, polytrauma, age of patient, implants availability, surgeons experience, desired anatomic and functional outcomes, and complication rates and cost [3]. Younger age groups (preschool going children) are usually treated with conservative measures like application of Hip spica and sometimes with Pavlic Harness in the neonatal age group [4]. Due to greater potential for healing and correction of angulation, conservative methods are preferable in younger age group [5]. However as the child age

increases the management paradigm shift from conservative to operative fixation. There are numbers of options for operative fixation includes external fixators, flexible and locked intramedullary nails, and compression and bridge plating [6]. Fixation allows early mobilization and faster rehabilitation. According to a survey of members of Pediatric Orthopedic Society of North America, Surgery is considered a preferred method for older children especially with high energy trauma.<sup>1</sup> There are various methods for surgical stabilization of pediatric femoral fractures but the method of choice should depend on decision making factors like associated injuries, fracture personality; as well as the skills and expertise of the surgeon. Flexible intramedullary nails have been used in the management of pediatric femoral shaft fractures. It behaves as an internal splint thus providing enough stability but on the other hand also allow motion for callus to be formed at the fracture site. It allows early ambulation with little risk of osteonecrosis, physeal injury and re-fractures [7]. Pin insertion site irritation is reported to be the most frequent complication associated with this method [8]. Titanium flexible intramedullary nails are no doubt an expensive option in a developing country like Pakistan. We have utilized

---

*Department of Orthopedic Khyber Teaching Hospital, Peshawar*

*Correspondence: Alamzeb Khan Swati*

*Email: alamzebdr@hotmail.com*

bent rush pins for the management of femur shaft fractures. The objective of this study was to assess the outcome of the children managed by intramedullary stabilization.

**METHODS**

This study was carried out on 40 pediatric aged patients having femoral fractures without any additional neurovascular injuries admitted from June 2009 to December 2010 through both out patient department and emergency. All the patients were diagnosed by means of anteroposterior and lateral views of plan X rays. After taking consent from ethical research committee informed consent was taken from the attendants of all patients and were prepared for the surgery. The surgery was performed under general anesthesia on traction table in supine position and use of image intensifier. Rush pins were selected for individual patient after doing measurements on x-rays. Length and diameter of the normal side was measured. The diameter at the narrowest part on antero-lateral and lateral film was multiplied by 0.4mm, which gave the diameter of the pin to be used. Rush pins were bent at two points before inserting it in the canal. A bend was made at the tip for making the entry easy. Pins were inserted by using the T-handle or hammer with rush pin inserter. Finally the tip at the insertion site was bent to avoid skin irritation. Patients were discharged on 2<sup>nd</sup> or 3<sup>rd</sup> postoperative day and followed in out patient department. Radiographs were done on follow up visit to assess the alignment and later to assess healing. Patients were allowed weight bearing after 4-6 weeks after confirmation of callus formation through radiographs. Patients were followed for at least 6 months. Complications were noted like pin site irritation and mal alignment. Outcome was

graded as excellent, successful or poor according to Flynn’s criteria (Table-1). The data was initially entered on a pre-formed Proforma and later on SPSS Version 17.0 had been used for data analysis.

**RESULTS**

There were 40 patients who underwent fixation of 41 femur fractures (one patient had bilateral fracture). Age ranges from 6 to 12 years with a mean age of 8.25 ± 5 SD years. There were 24 males and 16 females. There were 18(45%) simple spiral, 10(25%) simple oblique, 9 (22.5%) simple transverse, 2(5%) bending wedge and 1(2.5%) segmental fracture. Fractures were reduced by close technique in 19(47.5%) patients and remaining i-e 21(52.5%) patients required open reduction. Minor complications were observed in 19 patients and most of them had irritation at pin insertion site. Major complications were observed in 6 patients. Two patients lost reduction and required reoperation. Two patients had deep infection at the insertion site requiring debridement. Two patients had protruding nails, which was a constant source of pain at insertion site till removal of pins (Table no II). Outcome was graded as excellent in 23 patients (57.15%), successful in 12 patients (28.57%) and poor in 6 patients (14.28%) (Figure no. I).

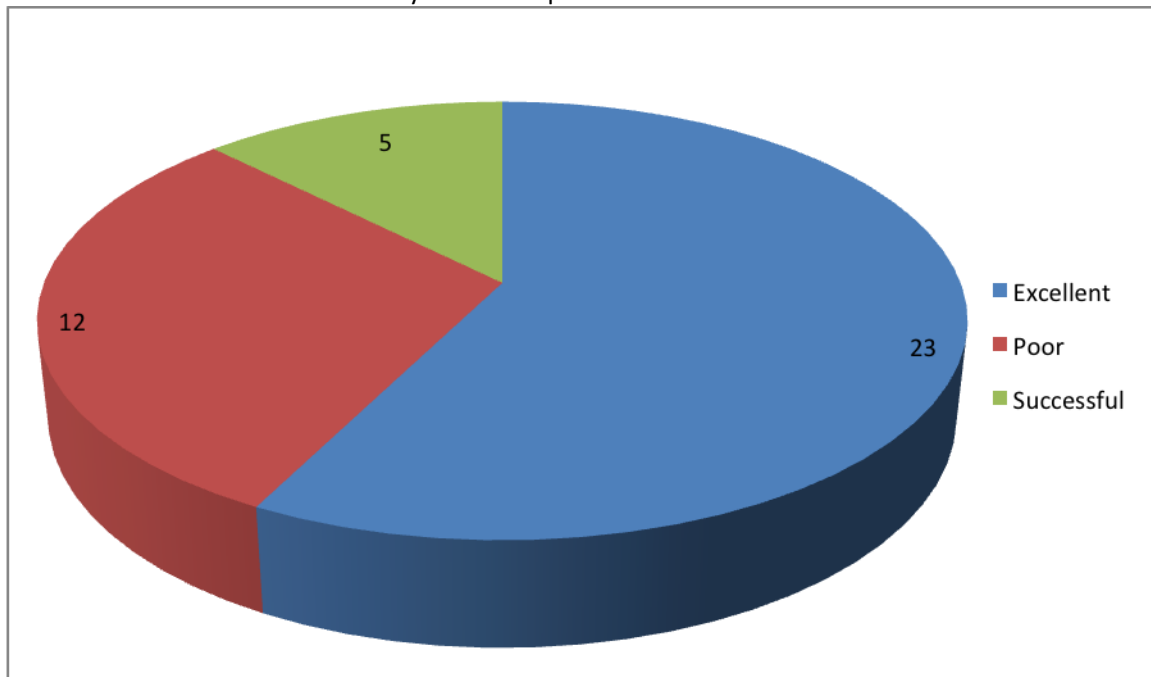
**Table- i: Flynn’s Criteria**

<b>Excellent</b>	<b>Successful</b>	<b>Poor</b>
<b>Limb length discrepancy</b> < 1.0 cm	<2.0 cm	>2.0 cm
<b>Sequence disorder</b> 5°	10°	>10°
<b>Pain</b> Absent	Absent	Present
<b>Complication</b> Absent	Mild	Major complication and/or extended period for resolvable morbidity

**Table II:** Complications of intramedullary fixation in pediatric femoral fractures N=40

Type of complications	Further categorization of types of complications	Number of patients	Percentage of patients
<b>Minor complications</b>		19	47.5 %
<b>Major complications</b>	Deep infection at the insertion site requiring debridement	2	5 %
	Protruding nails	2	5%
	Lost reduction	2	5%

**Figure 1:** Overall outcome of intramedullary fixation in pediatric femoral fractures N=40



## DISCUSSION

Forty patients were operated for femur fractures. Outcome was excellent in 23 patients, successful in 12 patients and poor in 6 patients. Minor complications were observed in 19 patients while major complications were observed in six patients. There are various options for the management of pediatric femoral fractures [14]. Hip spica application remained the main stay of treatment in early childhood. But as the child grows, conservative management becomes more difficult and operative stabilization serves as a better choice for most of femur shaft fractures. Prolonged immobilization, increase absence from school and poor nursing care associated with cast treatment shifted the paradigm towards operative fixation. Intramedullary fixation with flexible nails has been used with good results become the choice of stabilization in pediatric long bone fractures, particularly the femoral shaft fractures [9]. The availability and cost is no doubt a major issue in a developing country. We have utilized bent rush rods as a means of intramedullary stabilization in patients with femur shaft fractures. Khazzam 2009 evaluated the results of femur fixation in 135 children (138 fractures) [10]. Seventy-two patients were stabilized with ender nails while 66 patients with titanium elastic nails. They reported good results with low complication rate. In our study we also had excellent results in 57.15% while

successful in 28.57%. Major complications were observed in 6 patients. Swamy A 2012 utilized long k-wires as an alternative to elastic titanium nails in 14 patients for the treatment of femur shaft fractures [11]. He observed good results in 13 and satisfactory in 1 according to Flynn's criteria. Thapa SK 2015 reported their results of fixation of femur fractures in twenty children with elastic intramedullary nails [12]. The results were excellent in 60%, successful in 35% and poor in 5%. Heybeli M 2004 evaluated their results of 35 fractures in 34 patients managed by intramedullary elastic nails in pediatric femoral fractures [13]. found encouraging results with intramedullary fixation of pediatric femoral fractures.

Small number of patients was one of the limitations of our study.

## CONCLUSION

Intramedullary fixation of pediatric femoral fractures with rush rods showed good results allowing early ambulation and avoid prolonged immobilization associated with cast management. However pin site irritation remained a frequent complication associated with this procedure.

## REFERENCES

1. Sela Y, Hershkovich O, Sher-Lurie N, Schindler A, Givon U. Pediatric femoral shaft fractures:

- treatment strategies according to age - 13 years of experience in one medical center. *Journal of Orthopaedic Surgery and Research*. July 2013;8:23. DOI:10.1186/1749-799X-8-23.
2. Kumar S, Anand T, Singh S. Comparative Study Using Intramedullary K-wire Fixation Over Titanium Elastic Nail in Paediatric Shaft Femur Fractures. *J Clin Diagn Res*. 2014 Nov;8(11):LC08-10. doi: 10.7860/JCDR/2014/9687.5119.
  3. Bezabeh B, Wamisho BL, Coles MJM. Treatment of Adult Femoral Shaft Fractures Using the Perkins Traction at Addis Ababa Tikur Anbessa University Hospital: The Ethiopian Experience. *International Surgery*. 2012;97(1):78-85. doi:10.9738/CC48.1.
  4. Chao Nan W, Jian Jun C, Jin Feng Z, hui Bin T, Yan Bo F, Xianhong Yi, Femoral Fractures in Infants : A Comparison of Bryant Traction and modified Pavlik Harness, *Acta Orthopædica Belgica*, Vol. 80 - 1 – 2014.
  5. Bhuyan BK, Mohan Singh S. Titanium elastic nailing in pediatric femoral diaphyseal fractures in the age group of 5–16 years – A short term study. *Journal of Clinical Orthopaedics and Trauma*. 2014;5(4):203-210. doi:10.1016/j.jcot.2014.08.001.
  6. James H Beaty. Operative Treatment of Femoral Shaft Fractures in Children and Adolescents, *Clinical Orthopaedics and Related Research* (Impact Factor: 2.77). 06/2005; 434(434):114-22. DOI: 10.1097/01.blo.0000163463.05141.1c
  7. Park H, Kim HW. Treatment of Femoral Shaft Fracture with an Interlocking Humeral Nail in Older Children and Adolescents. *Yonsei Medical Journal*. 2012;53(2):408-415. doi: 10.3349/ymj.2012.53.2.408.
  8. Lohiya R, Bachhal V, Khan U, Deepak Kumar, Vishwapriya Vijayvargiya, Sohan S Sankhala. Flexible intramedullary nailing in paediatric femoral fractures. A report of 73 cases. *Journal of Orthopaedic Surgery and Research*. 2011;6:64. doi:10.1186/1749-799X-6-64.
  9. Saikia, KC. "Titanium Elastic Nailing in Femoral Diaphyseal Fractures of Children in 6-16 Years of Age." *Indian Journal of Orthopaedics* 41.4 (2007): 381–385. *PMC*. Web. 26 Nov. 2015.
  10. Michael Khazzam, Channing Tassone, Xue C Liu ,Roger Lyon, Brian Freeto, jeffery Schwab, John Thometz , Use of flexible intramedullary nail fixation in treating femur fractures in children ,*American journal of orthopedics* (Belle Mead, N.J.) 04/2009; 38(3):E49-55.
  11. Swamy A. Management of pediatric femoral shaft fractures with long intramedullary kirshner wires. *The Libyan Journal of Medicine*. 2012;7:10.3402/ljm.v7i0.17275. doi:10.3402/ljm.v7i0.17275.
  12. Thapa SK, Poudel KP, Marasini RP, Dhakal S, Shrestha R. Paediatric diaphyseal femur fracture treated with intramedullary titanium elastic nail system. *JCMS Nepal*. 2015;11(2):20-22.
  13. Heybeli M, Muratli HH, Celebi L, Gülçek S, Biçimoğlu A, The results of intramedullary fixation with titanium elastic nails in children with femoral fractures.*Acta Orthop Traumatol Turc*. 2004;38(3):178-87.
  14. Kocher MS, Sink EL, Blasler RD, Luhmann SJ, Mehlman CT, Scher DM, et al, Treatment of pediatric diaphyseal femur fractures. *J Am Acad Orthop Surg*. 2009 Nov;17(11):718-25.